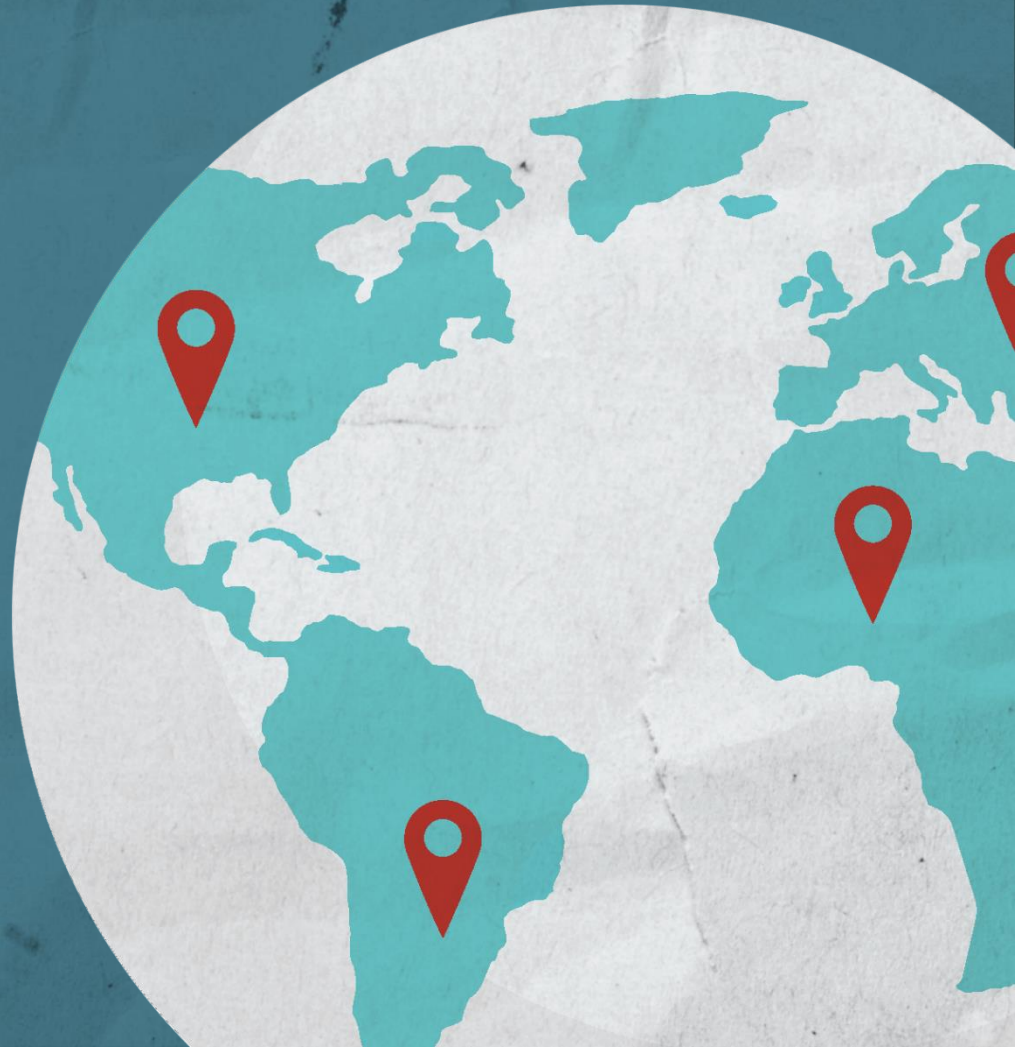

MPOX

Mpox 101: What Clinicians Need to Know



Source material for each slide is listed in the reference section at the end of this presentation by slide number. Unnumbered references refer to the whole slide.

Table of Contents

• Background.....	4
• Epidemiology.....	13
• 2022 Mpox Outbreak.....	18
• Evaluation and Diagnosis for Current Outbreak.....	26
• Differential Diagnosis.....	36
• Mpox and Mpox Look-Alikes.....	40
• Treatment.....	55
• Mpox Vaccination.....	67
• Vaccination Prior to Exposure.....	78
• Post-Exposure Prophylaxis (PEP) and Monitoring.....	82
• Infection Control, Isolation, and Monitoring.....	92
• References.....	101

Background

Mpox Virus

- Genus: *Orthopoxvirus*
- Family: *Poxviridae*
- Discovered in 1958 after two pox-like disease outbreaks in research monkey colonies
- Specific animal reservoir unknown, but likely small African mammals
- On November 28, 2022, the World Health Organization implemented a new preferred term “mpox” to reduce racist and stigmatizing language and other issues associated with the prior terminology

Other notable *Orthopoxviridae*

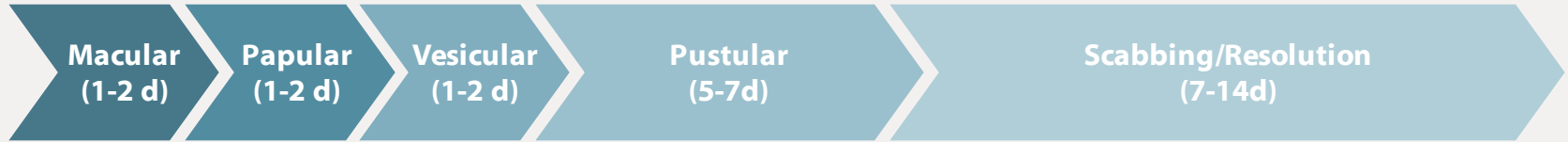- *Variola virus* (smallpox agent)
- *Vaccinia virus* (used in the smallpox vaccine)
- *Cowpox virus*

Historical Clinical Manifestations (1/2)

- Incubation period: 3–17 days¹
- Illness duration: 2–4 weeks²
- Development of initial symptoms marks beginning of prodromal period
 - Fever
 - Malaise
 - Headache
 - Weakness
- Febrile prodrome lasts 1–4 days
- Lymphadenopathy: generalized or localized to several areas (e.g., neck and armpit)

Historical Clinical Manifestations (2/2)

- Rash appears shortly *after* prodrome
 - Lesions develop anywhere on the body but most commonly on the face and extremities, including palms and soles
 - Clusters of lesions in one area begin simultaneously and evolve together
 - Lesion evolution

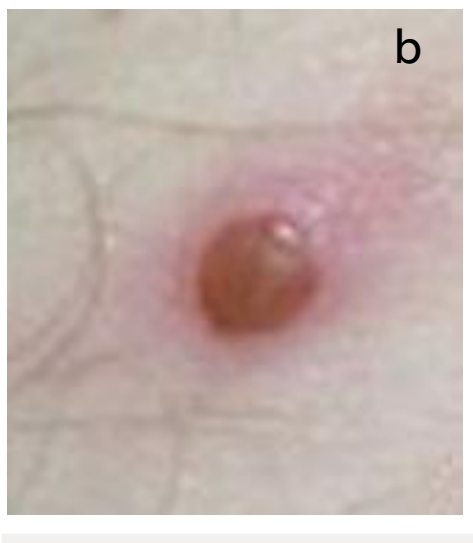
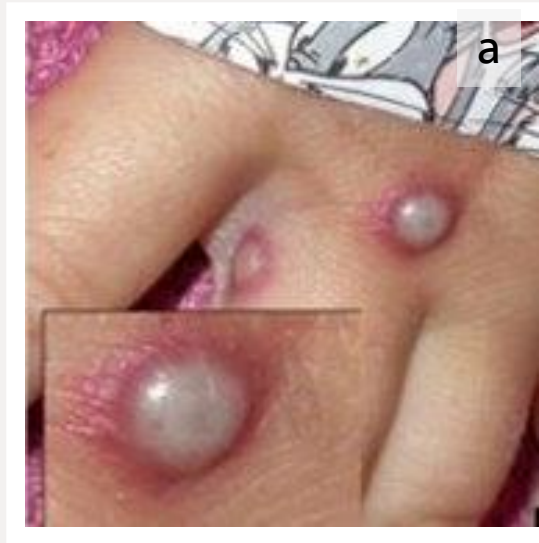

- Lesions are
 - Well circumscribed, deep seated, and often umbilicated
 - Often painful, then become pruritic during the healing phase

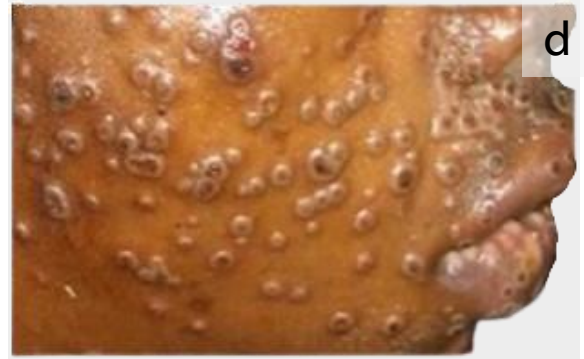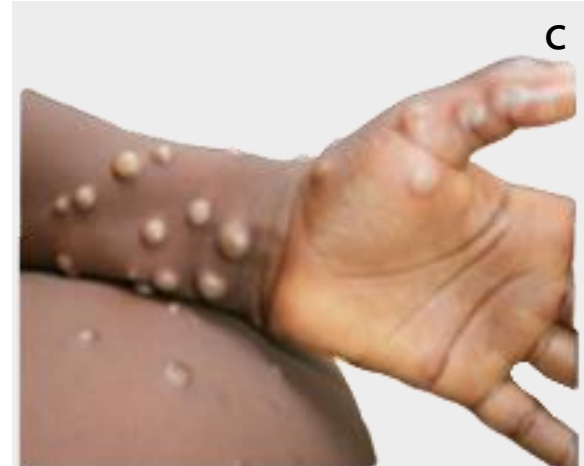Classic Rash Presentation

Mpox lesions are typically **firm** because they arise from deep in the dermis

Photo Credits a-d: [CDC](https://www.cdc.gov)



Lesions seen in the 2003 U.S. mpox outbreak



Lesions seen in endemic countries

Patients at Risk for Severe Mpox

- People with:
 - Underlying medical conditions
 - Inadequately treated HIV (CD4+ counts < 350 cells/mm³)
 - Moderate or severe primary immunodeficiency
 - Immunosuppression (e.g., organ transplant, therapy for autoimmune disorder, chemotherapy)
 - Lesions on certain surfaces (e.g., penile foreskin, urethral meatus, or vulva)
 - History of atopic dermatitis, eczema, or extensive breaks in the dermal barrier

Mpox Complications: Ocular

- Ocular mpox can cause conjunctivitis, blepharitis, keratitis, corneal ulcer, corneal scarring, and loss of vision

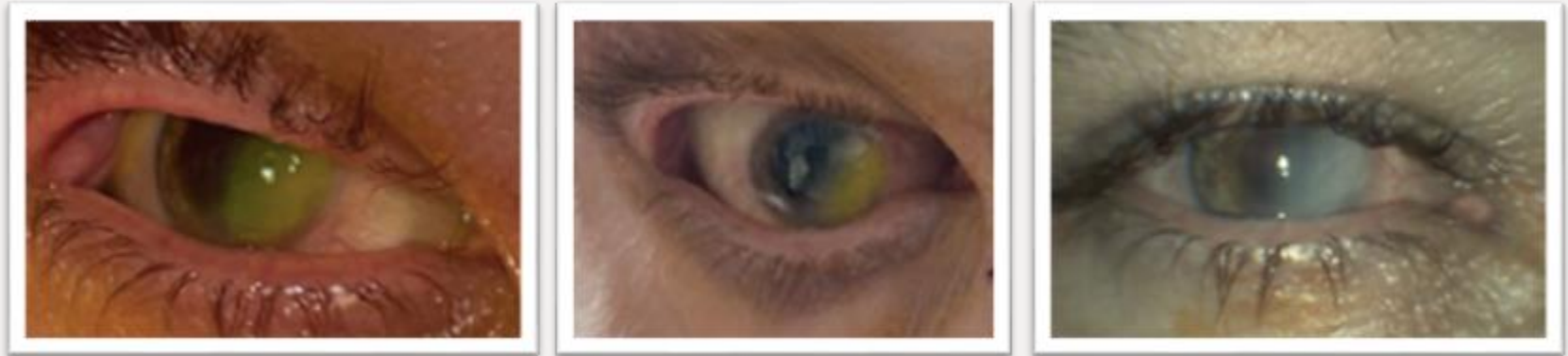

Photo Credits: Roddy Frankel, MD, PhD; Cynthia Pi, MD; Osasu Adah, MD; Rocio Bentivegna, MD;
Ophthalmology Department, St. Louis University

Mpox Complications: Severe Lesions

- Mucosal lesions may appear as painful ulcers in the oral, genital, and/or perianal areas and result in
 - Inability/difficulty to eat, urinate, and/or defecate due to pain and/or development of strictures
 - Myonecrosis and/or secondary infection if ulcers penetrate deep tissue
- Skin lesions may
 - Become confluent or necrotic
 - Require specialized wound care/transfer to burn unit depending on body area or total body surface area

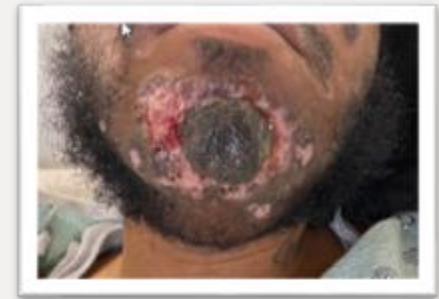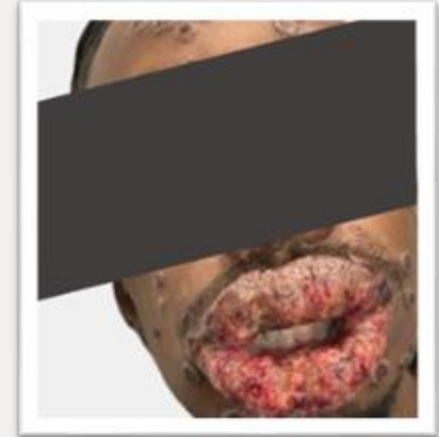


Photo credits: CDC

Mpox Complications: Other

- Neurologic complications may include encephalitis and/or myelitis
- Myopericarditis may present as chest pain/discomfort, shortness of breath, or palpitations
- Obstructions (most often in the lungs or gastrointestinal tract) secondary to
 - Ulcer-related strictures
 - Severe lymphadenopathy
 - Edema of surrounding tissue
- Sepsis/hemorrhagic disease

Epidemiology

Up-to-Date CDC Situation Summary

- [US Map & Case Count](#)¹
- [US Case Trends](#)²
- [Global Map & Case Count](#)³
- [Case Demographics](#)⁴
- [Vaccine Administration and Effectiveness](#)⁵
- [Laboratory Testing](#)⁶
- [Multi-National Mpox Outbreak Technical Reports](#)⁷

Transmission

- Mode: Direct or indirect contact with body fluids or lesion materials¹
- Risk of infection through contact with contaminated surfaces or objects is considered low²
- Transmission during brief interactions or between people in close proximity and for a long duration (such as passengers seated near a person with mpox on an airplane) is unlikely³
- How often mpox virus is spread via respiratory secretions is unknown³
- Patients may be infectious up to 4 days before symptom onset¹
- Patients remain infectious until lesions form scabs, scabs fall off, and a fresh layer of skin forms⁴

High Risk Exposure Examples for Health Care Providers (HCPs)

- Unprotected contact between an individual with **broken** skin or mucous membranes and an mpox patient's:
 - Skin lesions
 - Bodily Fluids
 - Soiled Linens
- Injury from sharp object that has had contact with skin lesions or bodily fluids of an mpox patient
- Being within 6 feet of a mpox patient without appropriate personal protective equipment (PPE; NIOSH approved N95 respirator or higher-level) during procedures which may:
 - Generate aerosols, such as intubation or CPR
 - Resuspend dried contaminants, such as shaking/changing soiled linens

Intermediate Risk Exposure Examples for HCPs

- Being within 6 feet of an unmasked patient with mpox for ≥ 3 hours without wearing appropriate PPE
- Having unprotected contact between an individual with **intact** skin and mucous membranes and an mpox patient's:
 - Skin lesions
 - Soiled Linens
 - Bodily Fluids
- Performing activities that result in contact with an mpox patient's body fluids or soiled material without appropriate PPE
 - Turning
 - Bathing
 - Assisting with a transfer

2022 Mpox Outbreak

2022 Mpox Outbreak Signs and Symptoms

- During this outbreak, mpox may present atypically
 - Characteristic rash present but often starts in mucosal areas
 - Genital
 - Perianal
 - Oral
 - Skin lesions are scattered or localized to a specific body site but not disseminated



Rash Presentations (1/2)

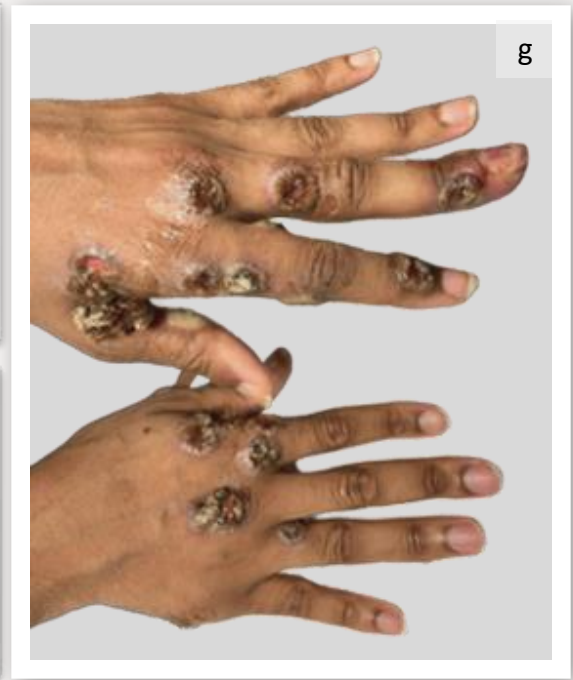
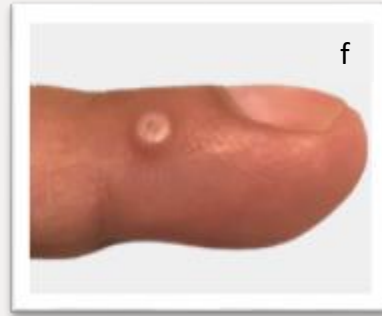
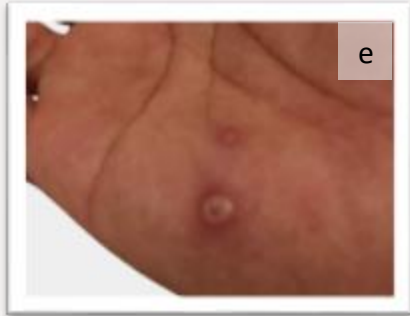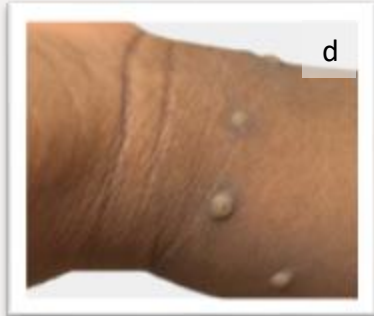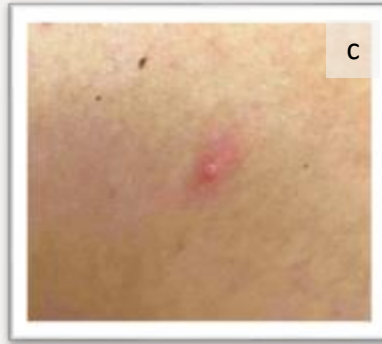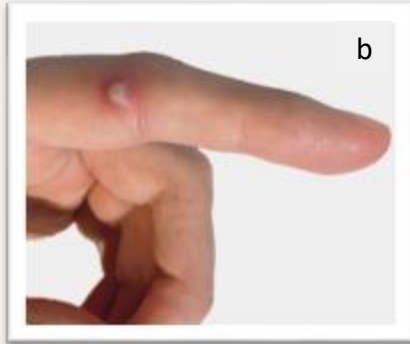


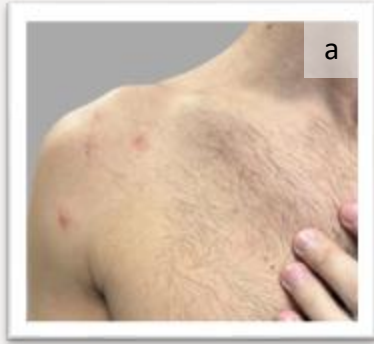Photo Credits: a-c) Basgoz et al.¹; d-f) CDC; g) Miller MJ et al.²

Rash Presentations (2/2)

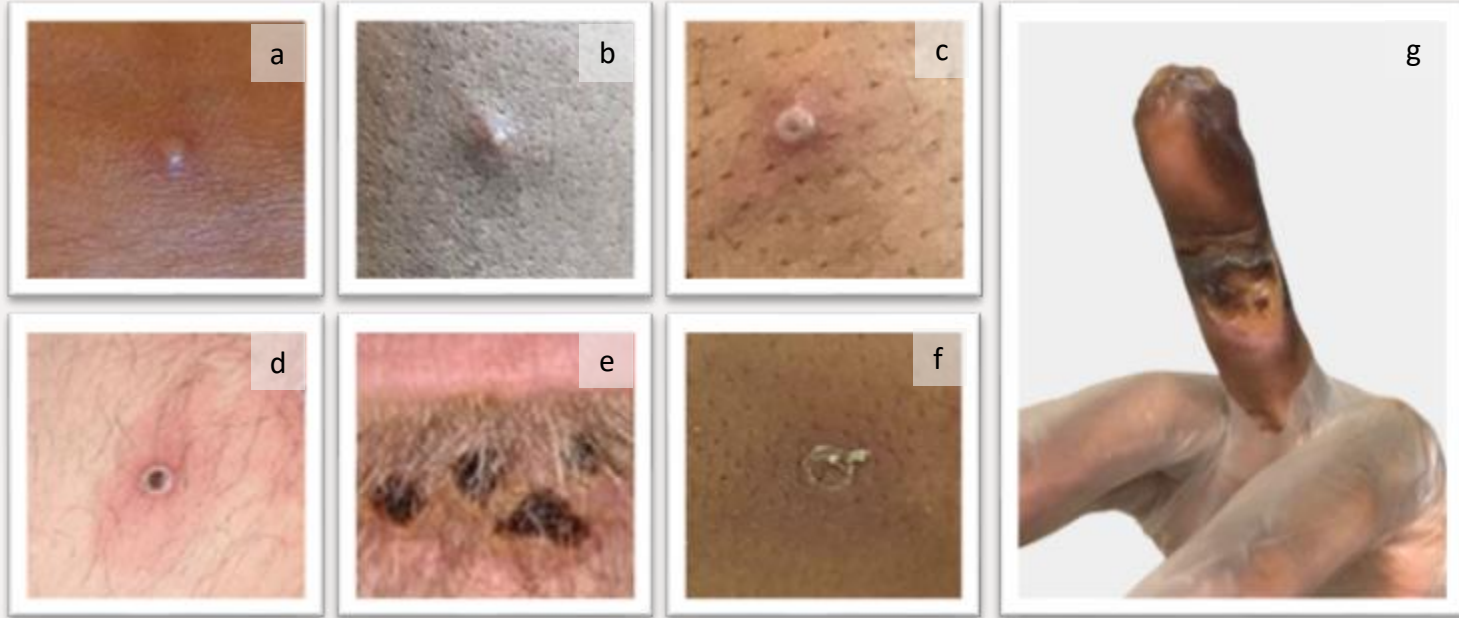

Photo Credits: a-f) UK Health Security Agency, g) CDC

Genital Lesions (1/2)

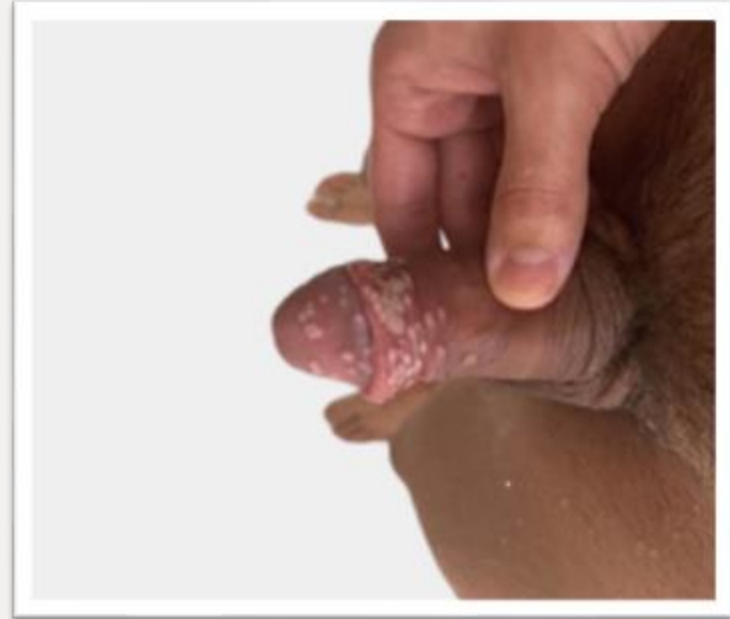
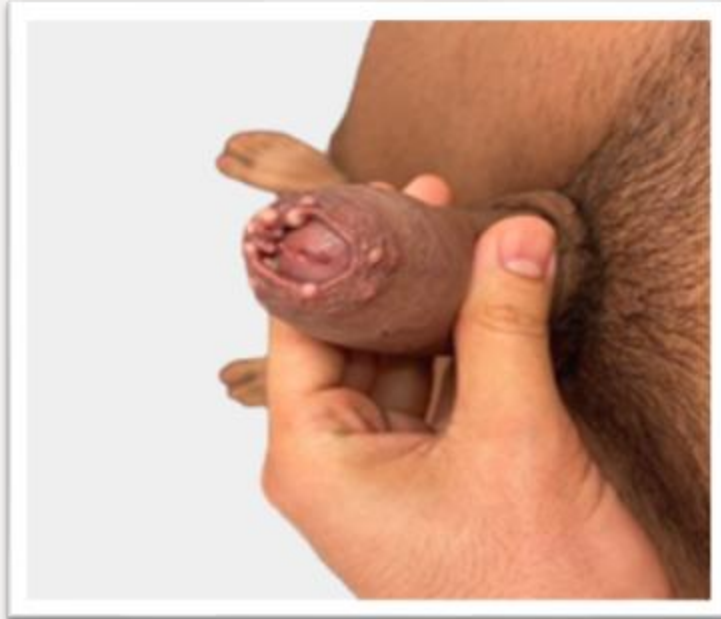
Photo Credits: DC Health and Wellness Center

Genital Lesions (2/2)

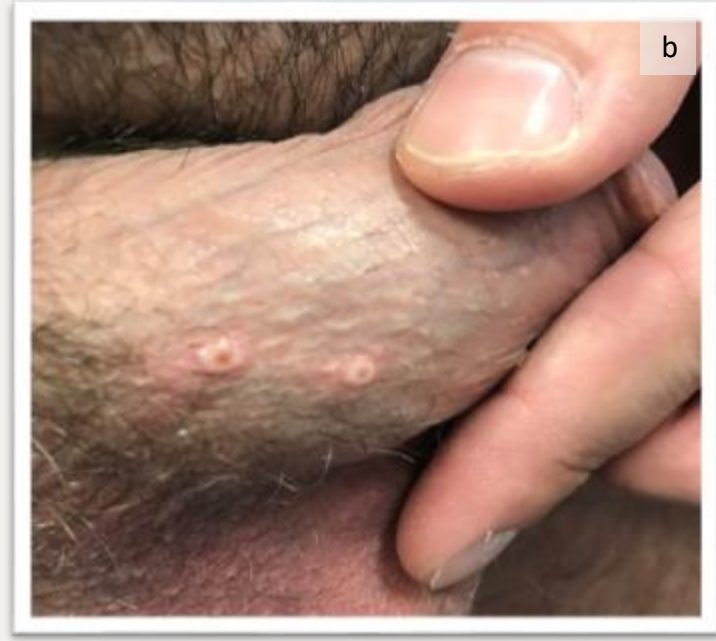
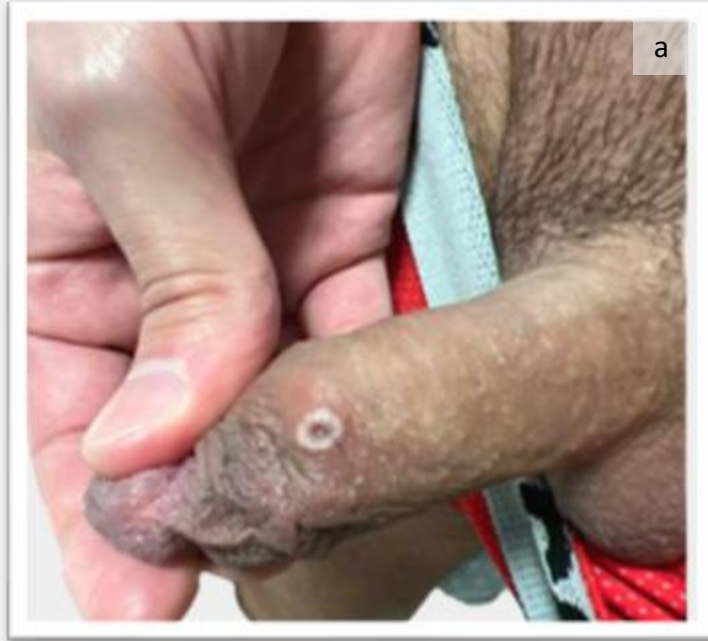
Photo Credits: a) Photo appears in Basgoz et al., b) DC Health and Wellness Center

Perianal Lesions

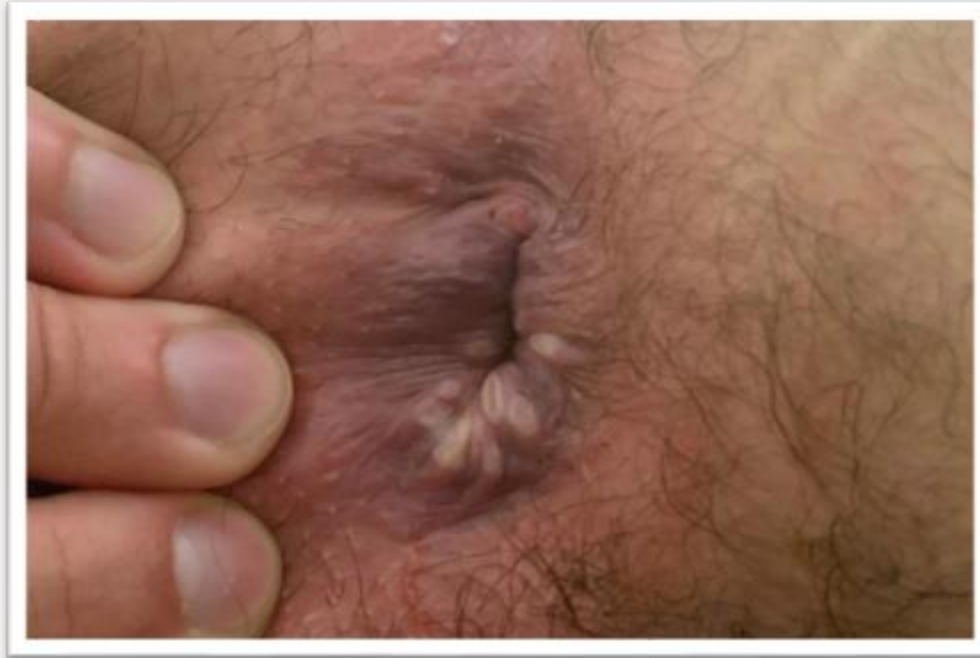
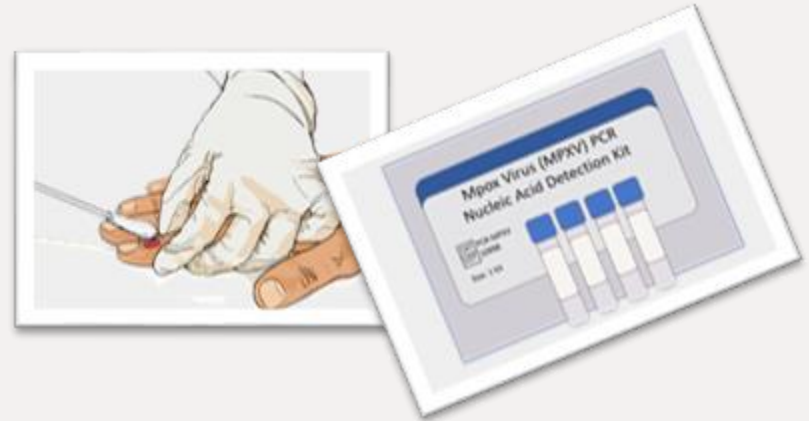
Photo Credit: DC Health and Wellness Center

Current U.S. Outbreak Response

- Surveillance
 - Case identification
 - Most cases have been identified in immunocompetent men who are gay, bisexual, and other men who have sex with men
 - Laboratory testing
- Containment
 - Isolation of cases
 - Contact tracing
- Mpox vaccine prior to exposure or as postexposure prophylaxis



Evaluation and Diagnosis for Current Outbreak

Clinical Recognition

- Clinicians seeing outpatients may be first to encounter patients with mpox
- Comprehensive patient social and sexual histories (including attendance at social gatherings) and physical examination are essential
 - Patients may have mild symptoms
 - Mpox may present similarly to sexually transmitted infections (STIs) or varicella zoster
 - Patients being evaluated for mpox should be tested for HIV and other STIs
- Notify the health department of suspected, probable, and confirmed mpox cases for
 - Case reporting
 - Help with laboratory testing

History of Present Illness

- Mild or absent prodromal symptoms
- Presenting symptoms may be consistent with proctitis and include
 - Anorectal pain
 - Tenesmus
 - Pruritis
- Presenting signs
 - Perianal vesicular, pustular, or ulcerative skin lesions
 - Rectal bleeding

Social History

- Sexual history
 - Gender and number of sex partners
 - History of HIV and other STIs
 - Engagement in sex work or sex trades
 - Sex associated with commercial sex venues, sex parties, group sex, etc.
- Living situation: congregate setting or homelessness
- Within 21 days of illness onset
 - Travel to a country with mpox (endemic or recently reported non-endemic)
 - Contact with an African-endemic wild animal or exotic pet (dead or live) or derivative products

Physical Examination

- Should be complete and include a thorough skin and mucosal (e.g., oral, genital, anal) examination in a well-lit room
 - Persons presenting with genital/perianal complaints may have clues in other bodily areas
- 2022 outbreak lesion characteristics:
 - Often scattered or localized, rather than diffuse
 - Often do not involve face or extremities
 - Typically of similar size and stage
 - May be painful, but painless lesions have been described

Case Definition

Suspect Case

- New characteristic rash OR
- Meets one of the epidemiologic criteria and has a high clinical suspicion for mpox

Probable Case

- Absence of recent orthopoxvirus exposure (e.g., vaccinia virus from ACAM2000 or JYNNEOS vaccination)
- Demonstrated presence of
 - Orthopoxvirus DNA by polymerase chain reaction testing of a clinical specimen **OR**
 - Orthopoxvirus using immunohistochemical or electron microscopy testing methods **OR**
 - Detectable levels of anti-orthopoxvirus IgM antibody during the period of 4 to 56 days after rash onset

Confirmed Case

- Demonstrated presence of mpox virus DNA by polymerase chain reaction testing or Next-Generation sequencing of a clinical specimen OR
- Isolation of mpox virus in culture from a clinical specimen

Epidemiologic Criteria

Within 21 days of illness onset

Had contact with a person(s) with a similar-appearing rash or who were diagnosed with confirmed or probable mpox **OR**

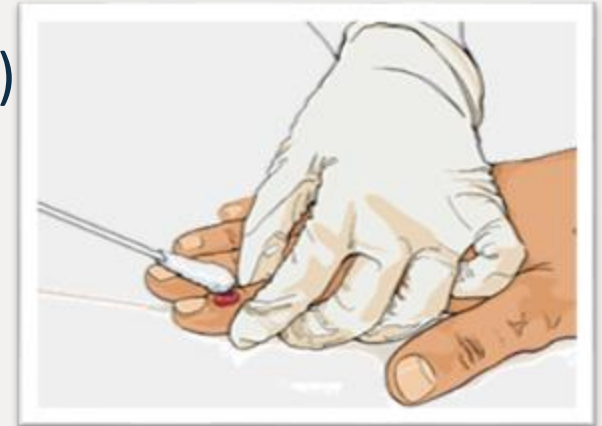
Had close or intimate in-person contact with individuals in a social network experiencing mpox activity; this includes men who have sex with men (MSM) who meet partners through online websites, digital applications (“apps”), or social events (e.g., a bar or party) **OR**

Traveled to a country with endemic mpox or reported non-endemic mpox **OR**

Had contact with an African-endemic wild animal or exotic pet (dead or live) or derivative products (e.g., game meat, creams, lotions, powders)

CDC-Issued Specimen Collection Guidelines

- Wear recommended personal protective equipment (PPE)¹
- Depending on the phase of the rash, use different procedures and materials to collect specimens²
- Do not unroof or aspirate lesions (or use sharp instruments for mpox testing) due to the risk for sharps injury³
- In severe cases, the CDC Infection Diseases Pathology Branch can assist when a biopsy is performed⁴



Testing for Mpox

- Skin lesion material is the recommended mpox virus specimen for initial [laboratory testing](#)¹ at either:
 - Commercial laboratories
 - At a facility within the [Laboratory Response Network](#)²
- Contact the appropriate [public health department](#)³ or commercial laboratory to determine criteria for acceptable specimens, as this may vary
- There is a specific protocol for [submitting specimens to the CDC](#),⁴ which may differ from that of local health departments
- **High clinical suspicion is sufficient to initiate treatment**

Additional Diagnostic Considerations¹

- Patients with rashes characteristic of more common infections (e.g., varicella zoster or STIs) should be evaluated for mpox
 - Diagnosis of an STI does not exclude mpox, as mpox infection may be concurrent
- Consider submitting lesion specimens, especially if epidemiologic risk factors for mpox are present
- Evaluate any individual presenting with genital, anal, or perianal ulcers; proctitis syndrome; or diffuse rash for STIs per the [2021 CDC STI Treatment Guidelines](#)²

Differential Diagnosis

Other Genital Ulcer Diseases

Infectious

- Herpes simplex virus (genital herpes)
- Primary or secondary syphilis
- Chancroid
- Lymphogranuloma venereum (LGV)
- Granuloma inguinale
- Molluscum contagiosum

Noninfectious

- Recurrent aphthous stomatitis
- Behçet's disease
- Trauma
- Squamous cell carcinoma
- Drug-induced
- Other

Clinicians should be aware that patients may have concurrent infections.

Genital Ulcer Disease Diagnostic Evaluation

- Syphilis serology tests
- Darkfield examination (or nucleic acid amplification test [NAAT], if available) from lesion exudate or tissue
- NAAT* or culture for genital herpes type 1 and 2
- Serologic testing for type-specific HSV antibody

*Preferred

Other Infections Causing Rash or Proctitis

Diffuse Rash

- Syphilis
- Herpes zoster
- Disseminated varicella zoster
- Disseminated herpes
- Molluscum contagiosum/other poxviruses
- Disseminated fungal infections
- Disseminated gonococcal infection
- Scabies
- Hand, foot, and mouth disease

Proctitis

- Gonorrhea
- Chlamydia (including LGV)
- HSV

Mpox and Mpox Look-Alikes

Macular/Papular Rashes: Mpox

- Early stage mpox can be macular
- Lesions are regional (anogenital, thighs, buttocks) or localized to a specific site but not disseminated
- 2022 outbreak rash often excludes palms and soles (unlike endemic mpox)

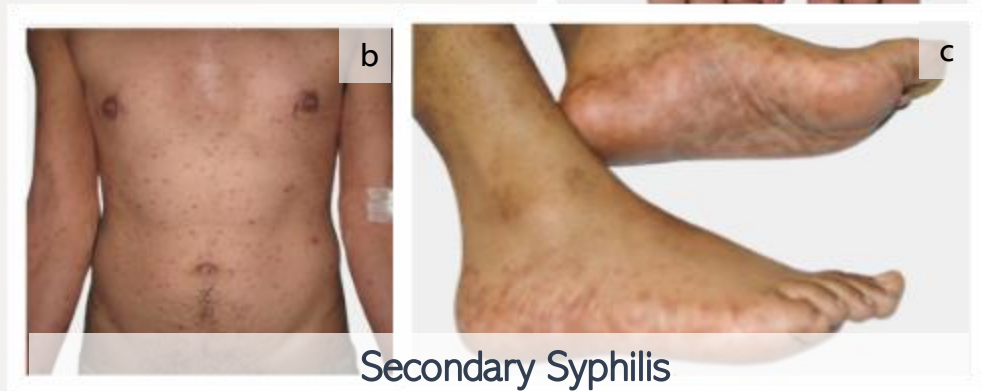
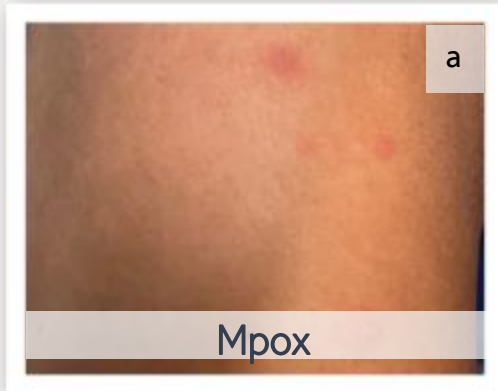

Photo Credits: a) CDC; b) Christopher Ried, MD, Orange County Health Care Agency; c) Scott Norton, MD, MPH; d) Public Health Image Library [#3508](#)

Macular/Papular Rashes: Secondary Syphilis

- Maculopapular rash is typically diffuse, symmetric, and involving trunk and extremities; includes palms and soles
- Localized, possibly scaly lesions may also occur
- May be pruritic

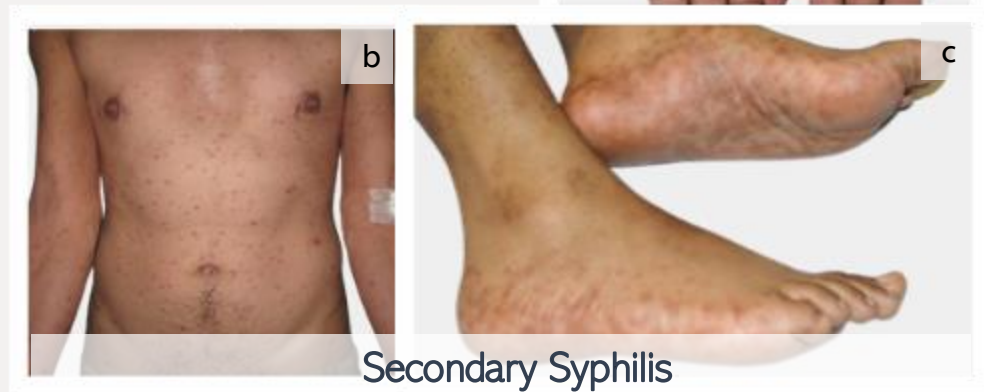
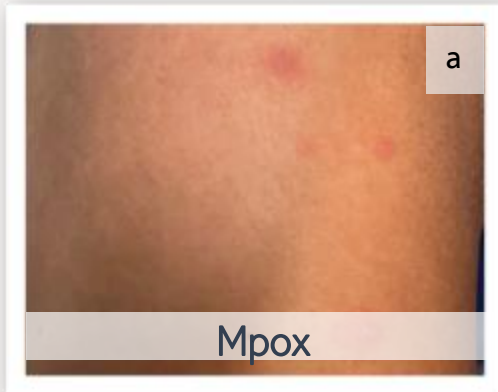
Photo Credits: a) CDC; b) Christopher Ried, MD, Orange County Health Care Agency; c) Scott Norton, MD, MPH; d) Public Health Image Library [#3508](#)

Vesicular Rash: Mpox

- Solitary vesicles are regionally distributed
- May or may not be painful
- Initially, vesicles are small with no central umbilication
- Often the first presenting symptom in the 2022 outbreak

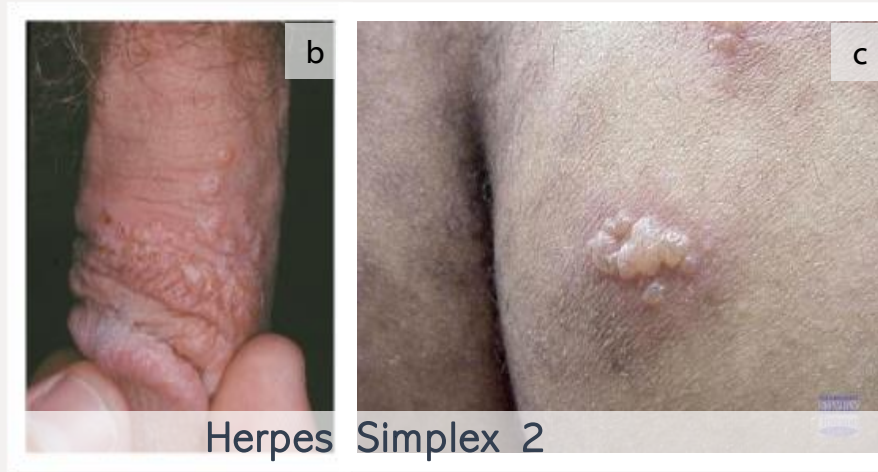
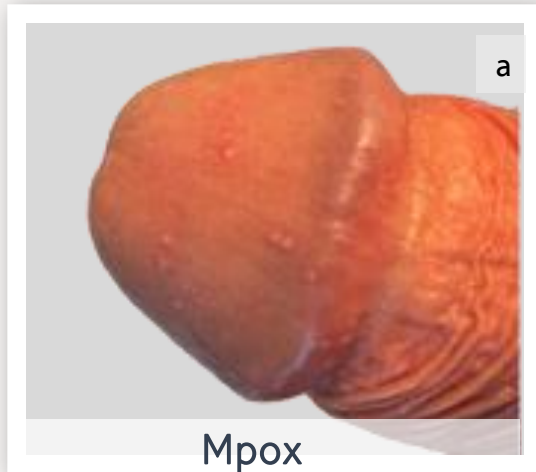

Photo credits: a) DC Health and Wellness Center; b) Scott Norton, MD, MPH;
c) Cincinnati STD/HIV Prevention Training Center

Vesicular Rash: Genital Herpes

- Grouped vesicles on an erythematous base of penile glans/shaft or vulva
- Associated with local pain and pruritis
- No early papule or late umbilical phase like mpox vesicles

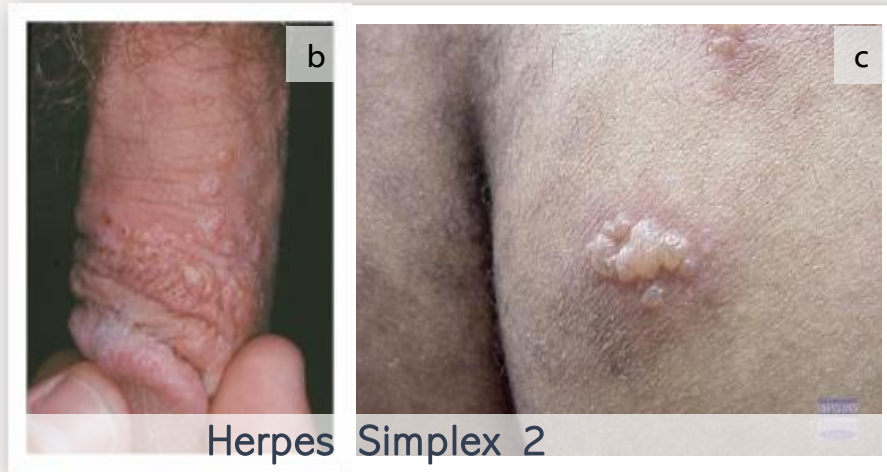
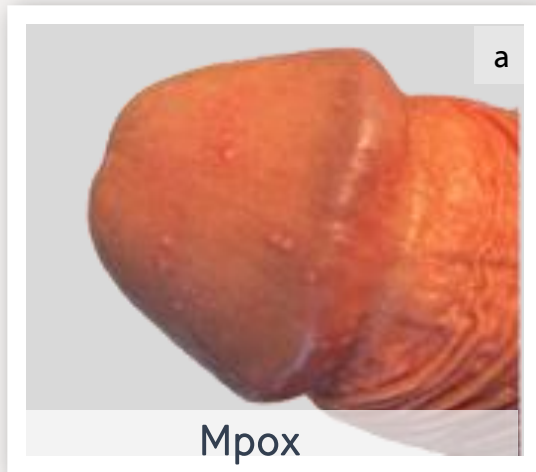
Photo credits: a) DC Health and Wellness Center; b) Scott Norton, MD, MPH;
c) Cincinnati STD/HIV Prevention Training Center

Pustular Rash: Mpox

- Well-circumscribed, deep-seated, **umbilicated**
- Develop and evolve simultaneously
- Any part of body (e.g., anogenital, palms, soles)
- Painful

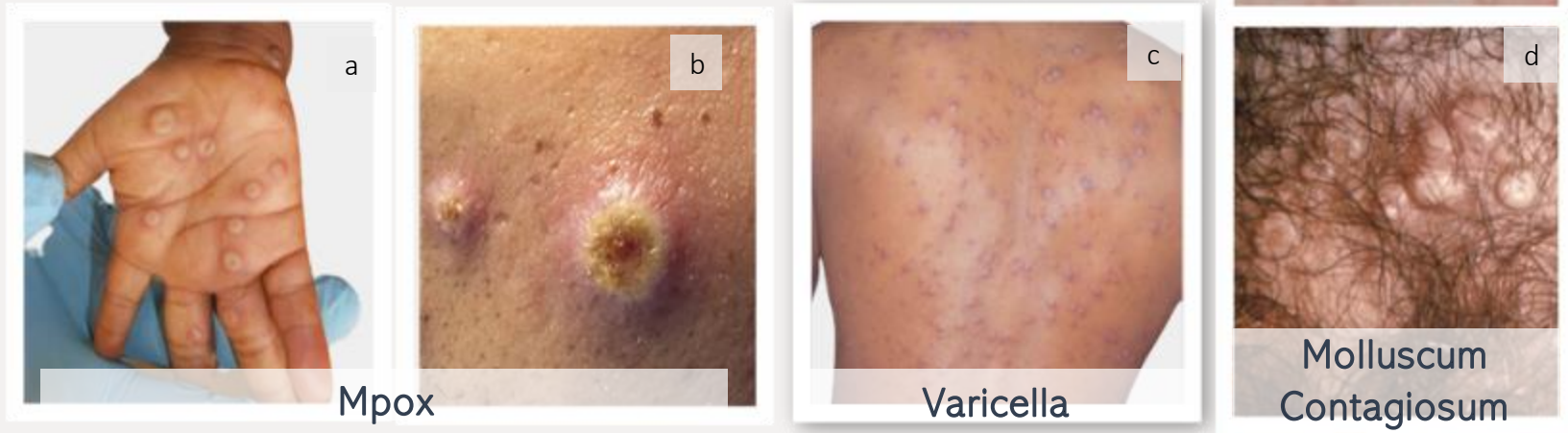

Photo Credits: a) CDC; b) CDC; c) [CDC Smallpox poster](#); d) Public Health Image Library [#16693](#);
e) Scott Norton, MD, MPH

Pustular Rash: Varicella

- Crops of pruritic vesicles on erythematous bases occur varying stages over several days
- Lesions can progress to pustules before crusting
- Febrile prodrome typically presents with the rash



Photo Credits: a) CDC; b) CDC; c) [CDC Smallpox poster](#); d) Public Health Image Library [#16693](#);
e) Scott Norton, MD, MPH

Pustular Rash: Molluscum Contagiosum

- Chronic, painless localized infection
- Firm, dome-shaped, umbilicated papules with shiny surfaces
- Appears anywhere except palms and soles

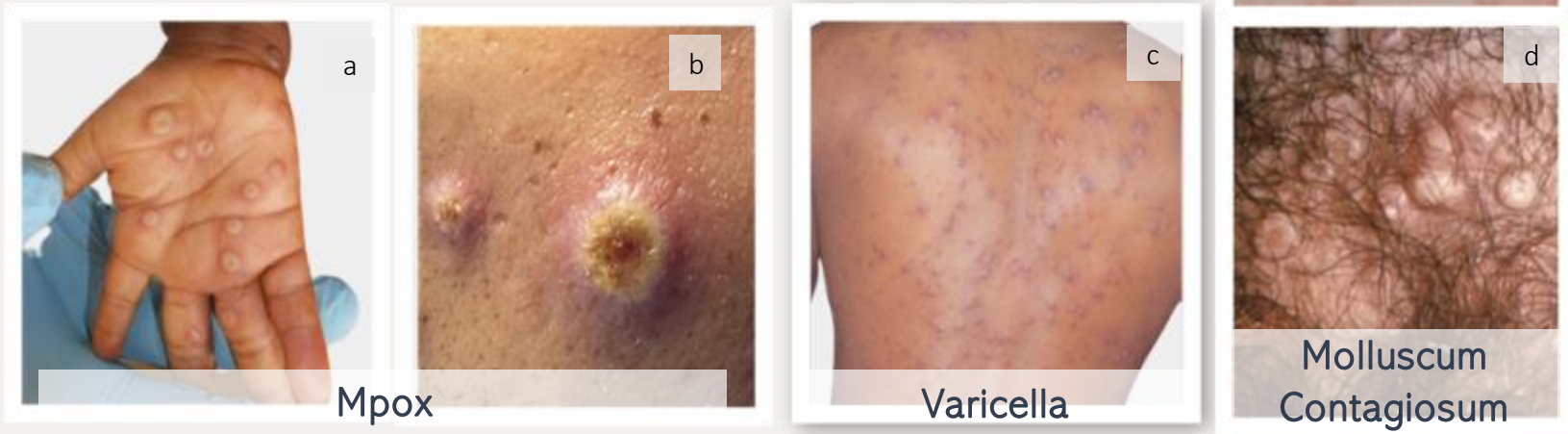

Photo Credits: a) CDC; b) CDC; c) [CDC Smallpox poster](#); d) Public Health Image Library [#16693](#);
e) Scott Norton, MD, MPH

Genital (Oral) Ulcer Disease: Mpox

- Genital, perianal, or facial lesions can coalesce into a large ulceration with crust and edema
- Can become secondarily infected

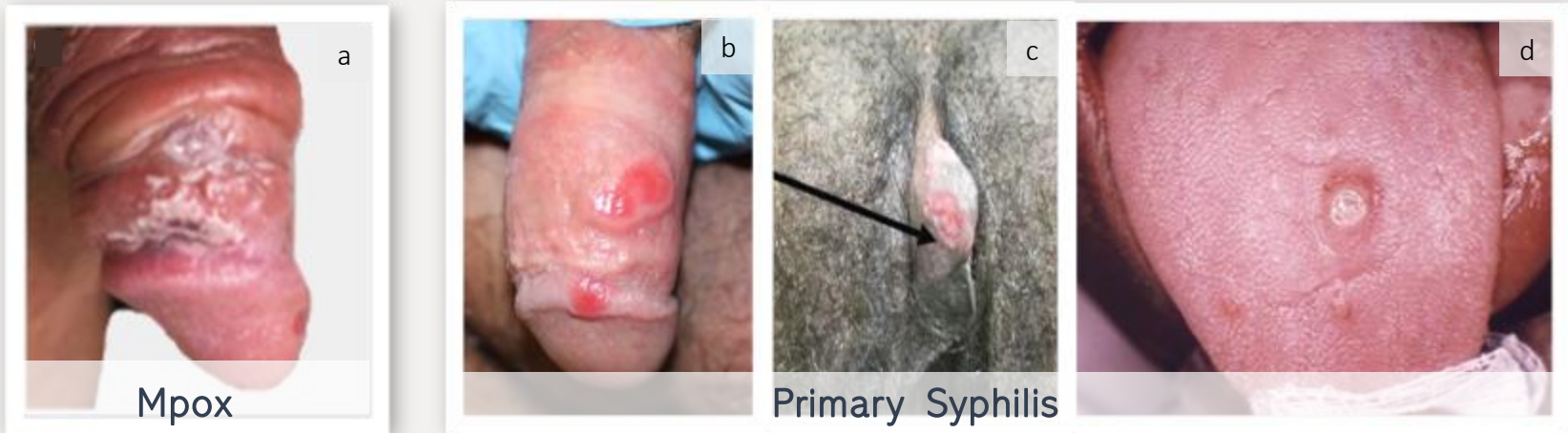


Photo Credit: a) Photo appears in Patrocínio-Jesus and Peruzzu¹; b) Christopher Ried, MD, Orange County Health Care Agency; c) CDC; d) Public Health Image Library [#12623](#)

Genital (Oral) Ulcer Disease: Primary Syphilis

- Classically, a single painless ulcer or chancre
- Can present with multiple, atypical, or painful lesions 1-2 cm in diameter with raised, indurated margins and non-exudative bases
- Usually on genitalia, but chancres can occur at any inoculation site

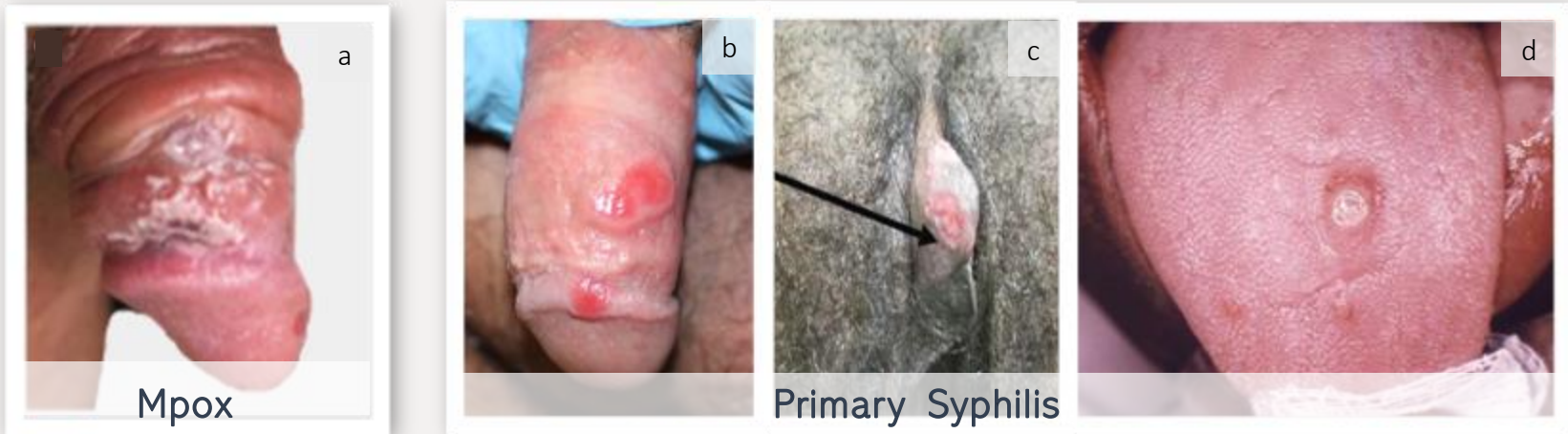


Photo Credit: a) Photo appears in Patrocinio-Jesus and Peruzzu¹; b) Christopher Ried, MD, Orange County Health Care Agency; c) CDC; d) Public Health Image Library [#12623](#)

Oral Mucosal Lesions: Mpox

- Thin-roofed white pustule on erythematous base
- Painful

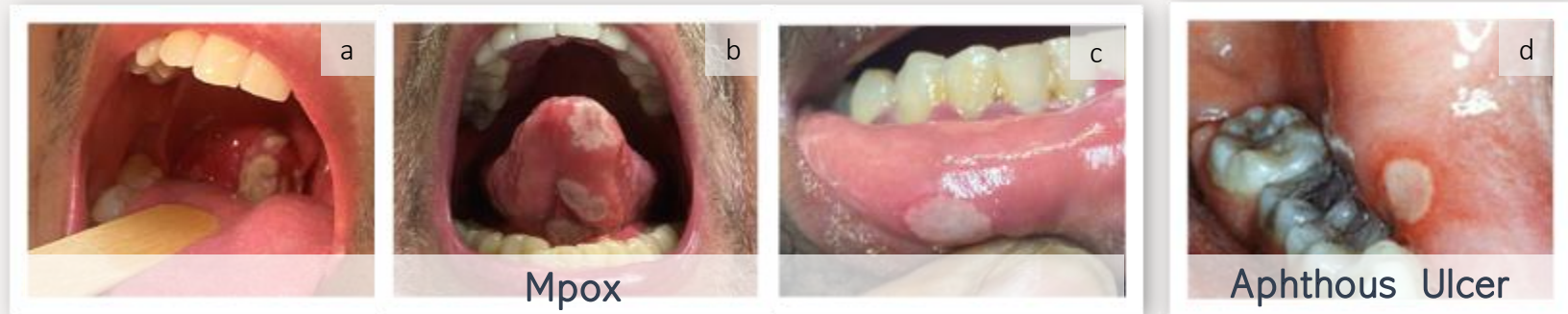


Photo Credits: a-c) CDC; d) CDC [mucositis slide deck](#)¹

Oral Mucosal Lesions: Aphthous Ulcer

- Unroofed mucous patches and whitish erosions on oral mucosa or tongue
- Painful

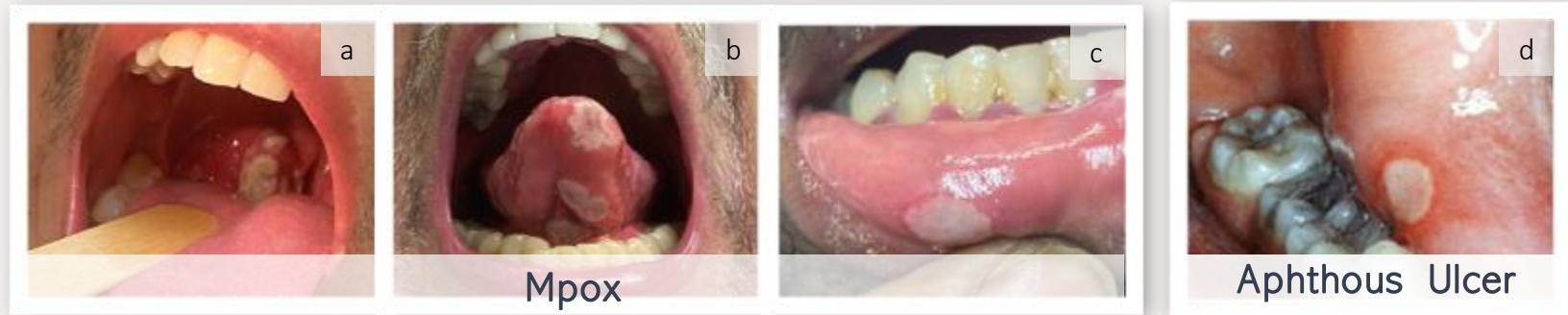


Photo Credits: a-c) CDC; d) CDC [mucositis slide deck](#)¹

Crusted Skin Lesions/Scabs: Mpox

- 7-14 days after the rash begins, mpox lesions crust over and scab before desquamation
- Can become pruritic at this stage

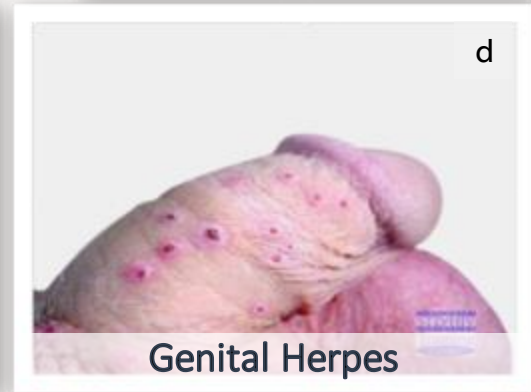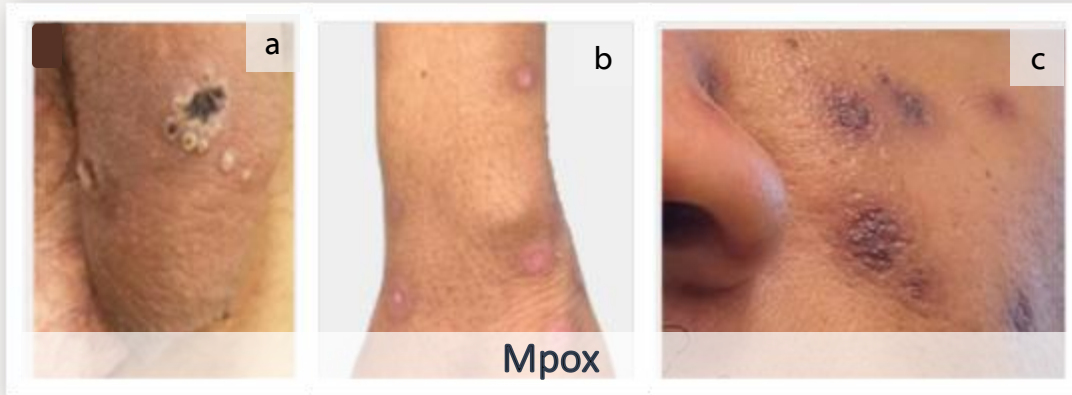
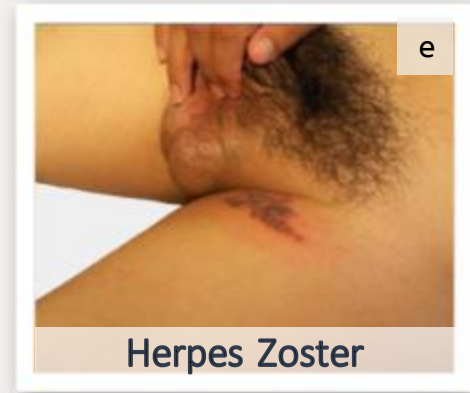


Photo Credits: a) Photo appears in Patrocínio-Jesus and Peruzzu¹; b & c) CDC; d) Cincinnati STD/HIV Prevention Training Center; e) CDC

Crusted Skin Lesions/Scabs: Genital Herpes

- Genital herpes primary infections resolve after a mean of 19 days; recurrent infections resolve after 10 days

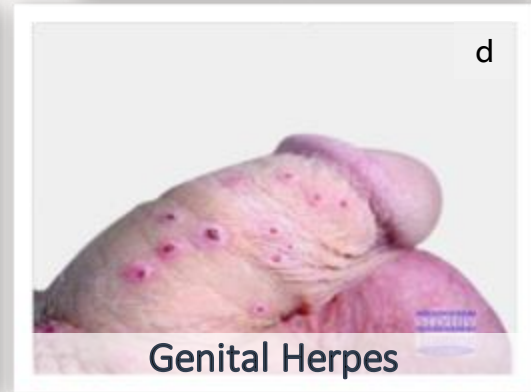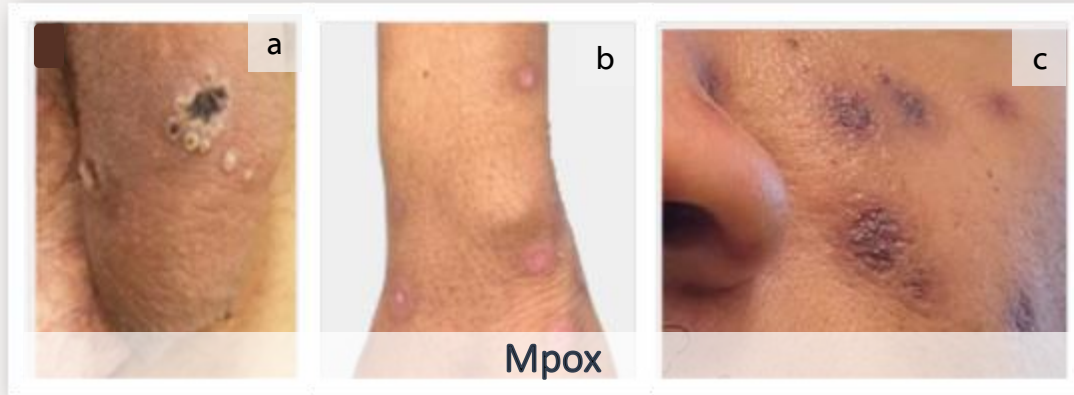
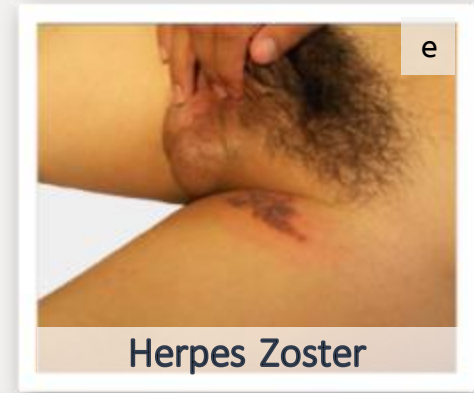


Photo Credits: a) Photo appears in Patrocínio-Jesus and Peruzzi¹; b & c) CDC; d) Cincinnati STD/HIV Prevention Training Center; e) CDC

Crusted Skin Lesions/Scabs: Herpes Zoster

- Begin as erythematous papules in a single dermatome
- Progress to grouped vesicles or bullae
- Most common presenting symptom is pain
- Associated with immunocompromise or advanced age

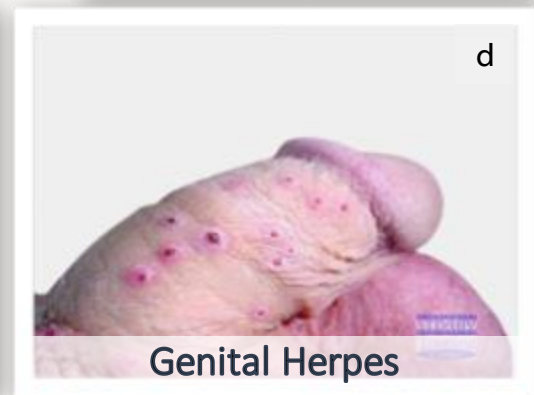
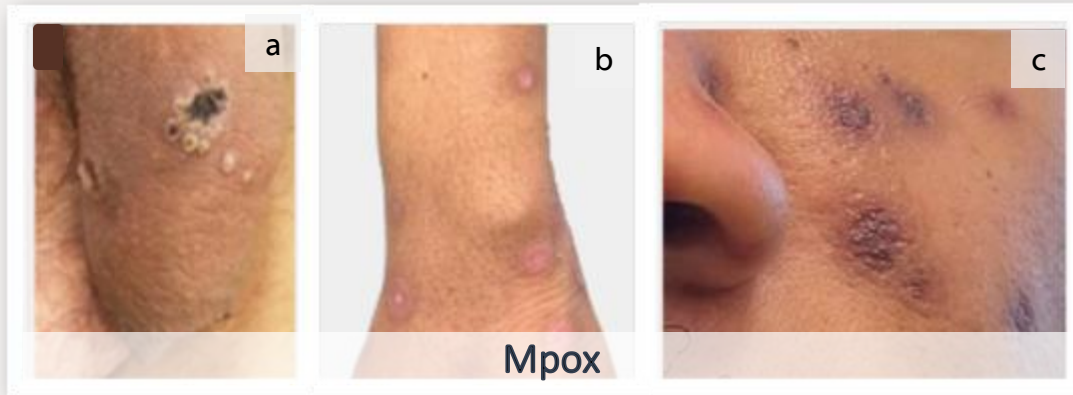
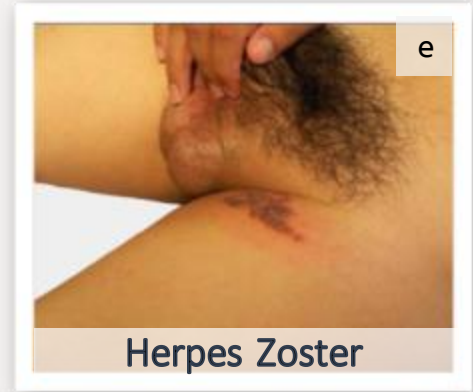


Photo Credits: a) Photo appears in Patrocínio-Jesus and Peruzzu¹; b & c) CDC; d) Cincinnati STD/HIV Prevention Training Center; e) CDC

Treatment

Mpox Prognostic Indicators (1/2)

- Mpox prognosis depends on multiple factors:
 - Previous mpox vaccination
 - Immune status (e.g., CD4+ count/viral load)
 - Concurrent illnesses and comorbidities
- Mpox infection is often mild and self-limiting without specific antiviral therapy¹
- Pain management,² skin care,³ and wound care are often vital components of mpox treatment plans

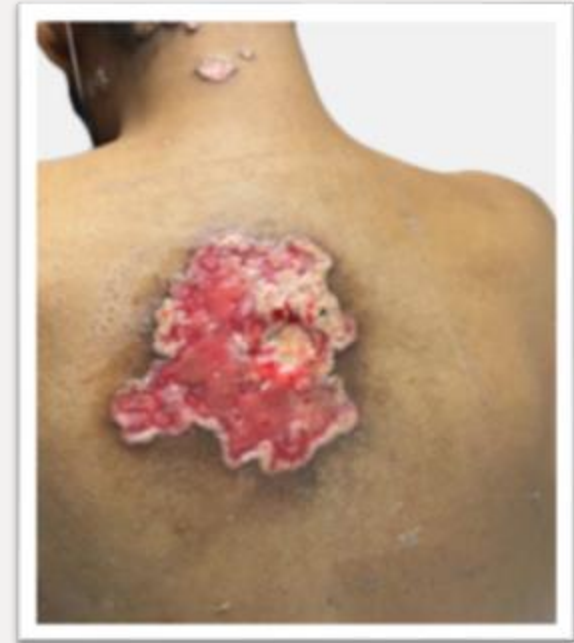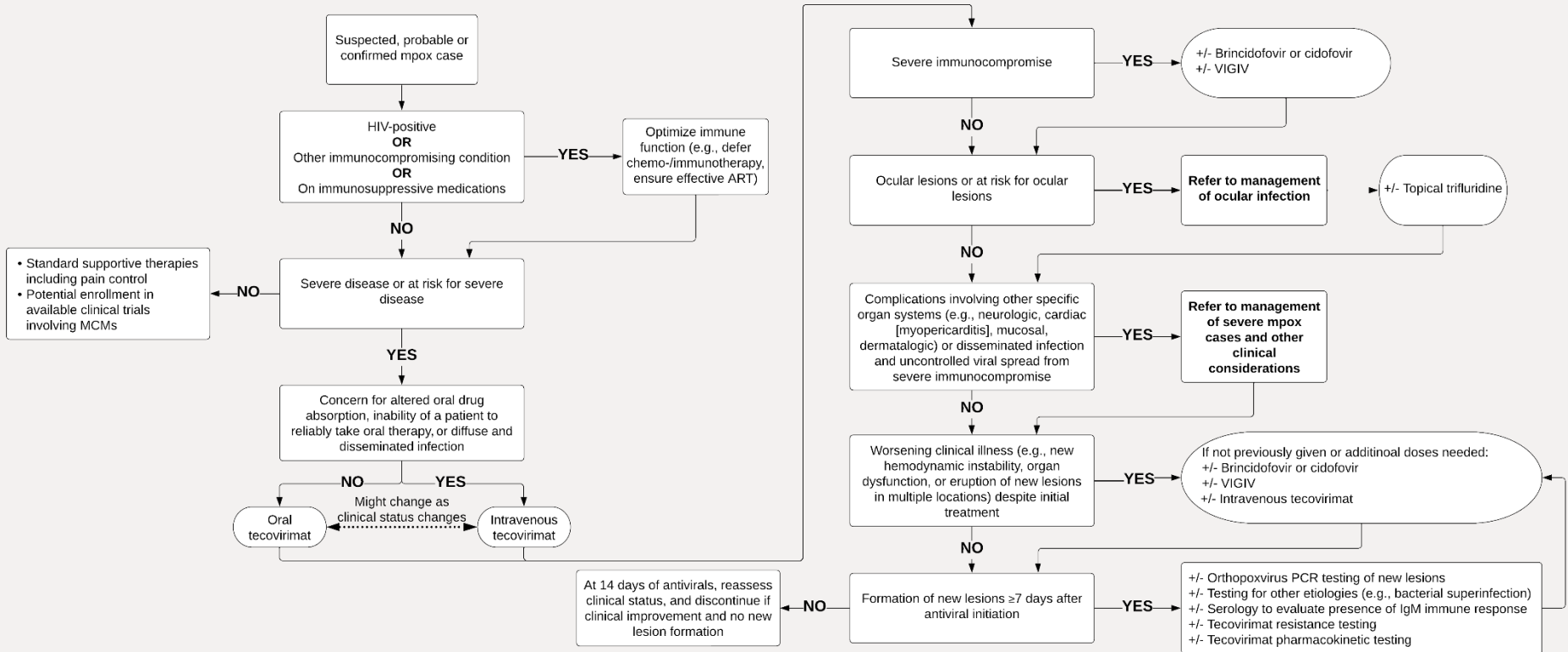


Photo Credits: Photo appears in
Miller MJ et al.

Mpox Prognostic Indicators (2/2)

- Patients with underlying immunocompromise are at risk for severe, systemic, protracted illness and death and likely need combination therapy
- CDC is available for clinical consultation, as needed (CDC Emergency Operations Center Phone: 770 488-7100; Email: poxvirus@cdc.gov)
- Prompt consultation with CDC is recommended for immunocompromised patients and patients at risk for severe mpox

Mpox Treatment Algorithm*



Optimize Immune Function

- For immunocompromised patients:
 - Facilitate competent native immunity (e.g., ensure persons with HIV are receiving effective antiretroviral therapy)
 - Limit the use of immunocompromising therapies (e.g., chemotherapy, corticosteroids)
- Doing this may:
 - Decrease duration of mpox therapies
 - Minimize morbidity and mortality

Tecovirimat

- Antiviral approved by the FDA for treatment of human smallpox
 - Also known as TPOXX or ST-246
 - Approved for adults and children weighing at least 3 kg
 - May be used for non-variola orthopoxvirus infection (e.g., mpox) under a CDC-held [Expanded Access Investigational New Drug Protocol](#)
- Mpox treatment efficacy
 - Animal studies suggest mortality benefit
 - Human case reports suggest reduced illness duration and viral shedding
- Mpox postexposure prophylaxis (PEP) efficacy is unstudied

Tecovirimat Should be Considered for Patients with:

Severe Disease

- Hemorrhagic disease
- Confluent lesions
- Sepsis
- Encephalitis
- Other conditions requiring hospitalization

Involvement of anatomic areas which might result in serious sequelae

- Eyes*
- Genitals
- Anus

High Risk for Severe Disease

- Severely immunocompromised
- Pregnant
- Breastfeeding
- Children <1 year
- Has a condition affecting skin integrity

One or more complications

- Secondary bacterial skin infection
- Gastroenteritis with severe nausea/vomiting, diarrhea, or dehydration
- Broncho-pneumonia;
- Concurrent disease or other comorbidities

*Trifluridine is the recommended therapy for ocular involvement

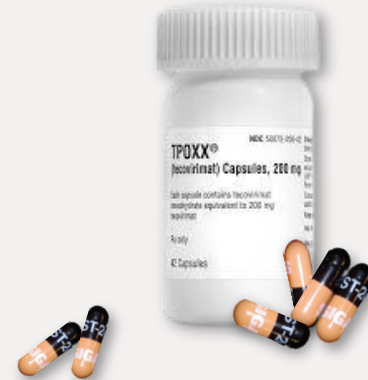Tecovirimat: Availability

- Oral capsules
 - Must be taken with a full, fatty meal for adequate absorption¹
 - May be opened and mixed with soft food for pediatric patients <13kg
 - Available through
 - [Study of Tecovirimat for Human Mpox Virus](#) ( **STOMP**)²
 - Some health departments (limited supplies)
- Oral and intravenous (IV) formulations available through the Strategic National Stockpile (SNS) via consultation/email with state/local health authorities or CDC as needed



Tecovirimat: Safety and Side Effects

- IV formulation contraindicated for creatinine clearance <30 mL/min
- Minor side effects in healthy subjects
 - Headache
 - Nausea
 - Abdominal pain
- Likely safe in pregnancy and breastfeeding without affecting fertility¹
- Not studied in pediatric patients



Cidofovir and Brincidofovir

Cidofovir

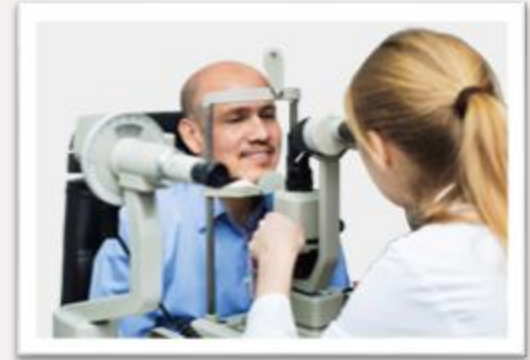- FDA approved for cytomegalovirus retinitis
- Demonstrated in vivo efficacy against orthopoxviruses
- Commercially available
- Limitations
 - Uncertain efficacy for treatment of mpox
 - Renal toxicity

Brincidofovir

- FDA approved for treatment of smallpox in children of all ages and adults
- In vitro and in vivo data suggest efficacy against orthopoxviruses
- Available through SNS following FDA authorization for single patient use
- Limitations
 - Uncertain efficacy for treatment of mpox
 - Hepatic toxicity

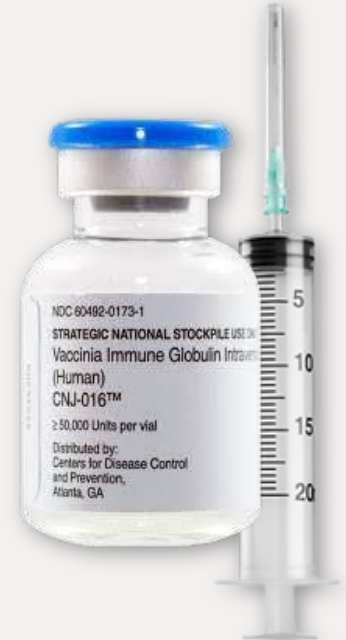
Ocular Mpox Treatment

- Ophthalmology referral strongly encouraged
- Tecovirimat dose needed to achieve therapeutic ocular concentration is unknown
- Avoid topical steroids to prevent viral persistence and corneal damage
- Trifluridine
 - FDA-approved nucleoside analogue for treatment of epithelial keratitis caused by herpes simplex virus
 - Preferred treatment for ocular orthopoxvirus infection (e.g., keratitis and conjunctivitis)
 - Use beyond recommended duration may cause corneal toxicity



Vaccinia Immune Globulin Intravenous (VIGIV)

- FDA-approved for the treatment of vaccinia vaccination (e.g., ACAM2000) complications such as
 - Eczema vaccinatum
 - Progressive vaccinia
 - Severe generalized vaccinia
- **May be used for prevention and treatment of orthopoxvirus infection complications** under a CDC-held [Expanded Access Investigational New Drug Protocol](#)
- Efficacy as pre-exposure prophylaxis (PrEP), PEP, or mpox treatment is unknown



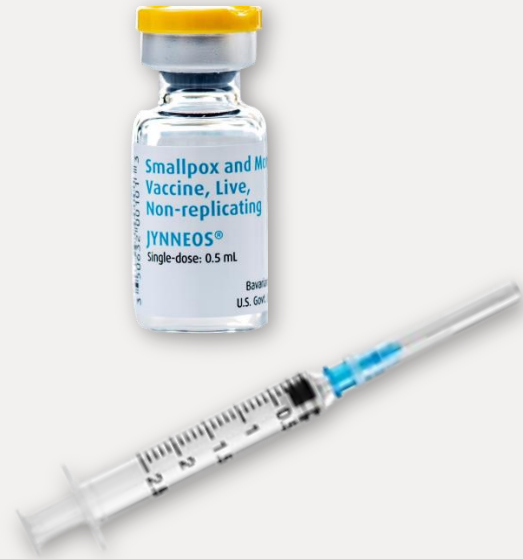Mpox Vaccination

JYNNEOS Vaccine

- Live virus vaccine
- Produced from the *replication-deficient* vaccinia virus strain Modified Vaccinia Ankara-Bavarian Nordic (MVA-BN; also known as IMVAMUNE, IMVANEX, MVA)
- FDA licensed in 2019 to prevent smallpox and mpox in adults ≥ 18 years old¹
- May be administered intradermally or subcutaneously for persons ≥ 18 and subcutaneously for persons < 18 under Emergency Use Authorization
- Administration in 2 doses at least 4 weeks apart
 - Standard regimen: subcutaneous² injections
 - Use only subcutaneous route for people with keloid history
 - **Preferred alternate** regimen: intradermal³ injections
- Can be used either *prior to* or *after* exposure (i.e., postexposure prophylaxis [PEP])

JYNNEOS Vaccine: Efficacy

- Vaccine effectiveness supported by:
 - Animal data
 - Immunogenicity studies
 - PEP efficacy data are limited
 - Used in mpox outbreaks outside the US in recent years
- Vaccine performance¹
 - Mpox incidence in unvaccinated persons was 7.4 times that of 1-dose recipients and 9.6 times that of 2-dose recipients¹
 - No differences in protection between intradermal and subcutaneous routes¹



JYNNEOS Vaccine: Safety

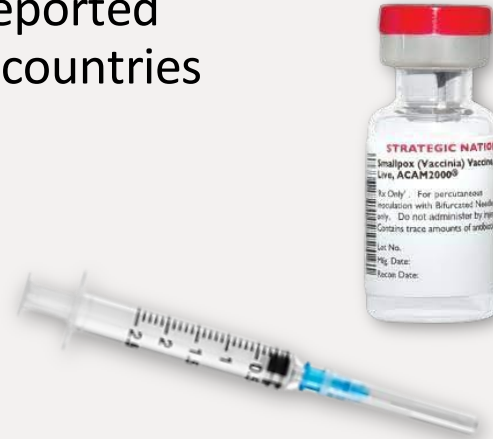- Safe for use in those who are immunocompromised or have atopic dermatitis
- Demonstrated to be safe in current outbreak
- Safety not established in:
 - Pregnant persons
 - Breastfeeding persons
 - Children
- Animal models using high doses showed no harm to a developing fetus
- Contraindicated in patients with prior severe allergic reaction to JYNNEOS
- **Use with caution in those with allergy to eggs, gentamicin, or ciprofloxacin**
 - Produced using chicken embryo fibroblast cells
 - Contains small amounts of gentamicin and ciprofloxacin

ACAM2000 Vaccine

- Live, *replicating* vaccine
- Administered as a single percutaneous dose using a multiple puncture “scarification” technique
- Licensed by FDA in 2007 for active smallpox immunization in ≥ 18 -year-olds
 - Has not been used in the current outbreak
- May be used for prevention of non-smallpox orthopoxviruses during an outbreak under a CDC-held Emergency Access Investigational New Drug Protocol

ACAM2000 Vaccine: Efficacy^{1,2}

- Vaccine effectiveness likely similar to that reported for other live smallpox vaccines in endemic countries (>85%)³
- PEP efficacy is not well studied in mpox



ACAM2000 Vaccine: Safety and Side Effects

Side Effect Profile	Contraindications
Myo/pericarditis (1 in 175) ¹	Pregnancy
Progressive vaccinia	Young children
Eczema vaccinatum	Immunocompromised
Postvaccinial encephalitis	Exfoliative skin condition
Fetal vaccinia	Known underlying heart disease (e.g., coronary artery disease or cardiomyopathy)
Inadvertent inoculation or autoinoculation	
Capable of person-to-person spread through close contact ²	

Eczema Vaccinatum from ACAM2000 Vaccine

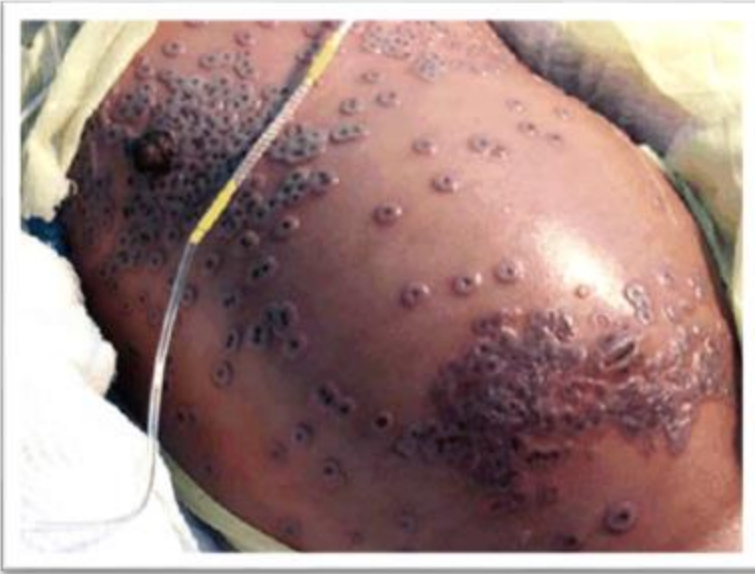

Photo Credit: CDC, [2007 MMWR](#)¹

- Photo showing 2-year-old household contact of ACAM2000 recipient
- The child had eczema
 - Increased risk of complications from vaccinia virus inoculation

Severe Vaccinia Virus Complications from Inadvertent Transmission

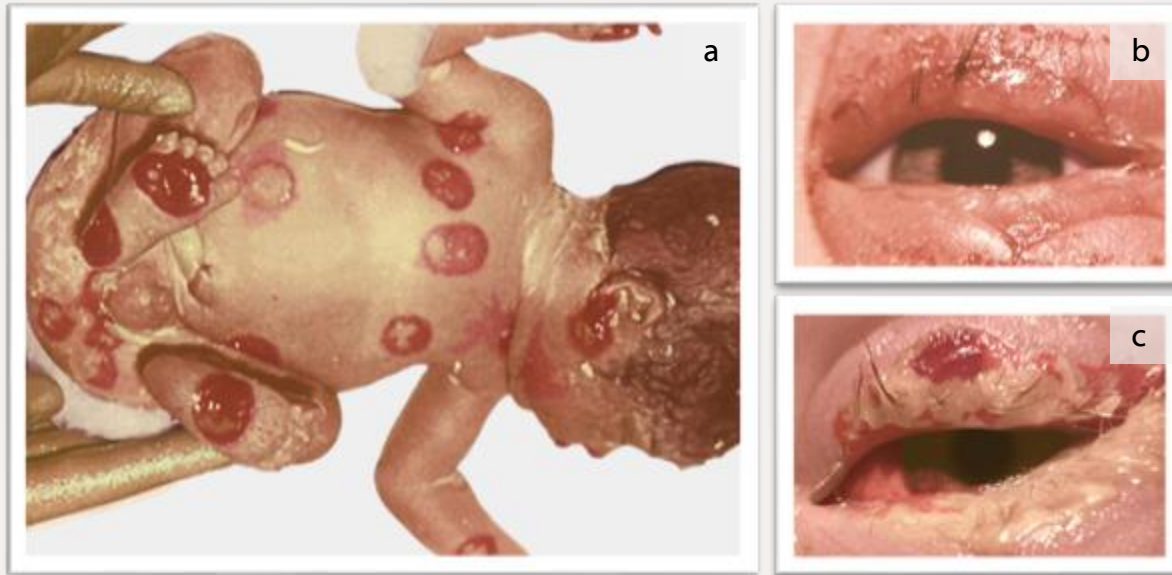


Photo credits: a) Fetal vaccinia, Public Health Image Library (PHIL) [#14269](#);
b) Ocular vaccinia from autoinoculation, PHIL [#3248](#); c) PHIL [#3247](#)

Contraindications: ACAM2000 and JYNNEOS

Contraindications for ACAM200 and JYNNEOS Table

Clinical characteristic	ACAM2000 Primary vaccination	ACAM2000 Revaccination	ACAM2000 Household Contacts with condition*	Contraindication to receipt of JYNNEOS
History or presence of atopic dermatitis	X	X	X	
Other active exfoliative skin conditions [†]	X	X	X	
Immunosuppression [§]	X	X	X	
Pregnancy [¶]	X	X	X	
Age <1 year**	X	X	X	
Breastfeeding ^{††}	X	X		
Serious vaccine component allergy	X	X		X
Known underlying heart disease (e.g., coronary artery disease or cardiomyopathy)	X	X		
Three or more known major cardiac risk factors ^{§§}	X			

Footnotes may be found in the notes section of this slide

Summary: ACAM2000 and JYNNEOS Vaccines

JYNNEOS is preferred over ACAM2000 because it has far fewer side effects

	ACAM2000	JYNNEOS
Vaccine virus	Replication-competent vaccinia virus	Replication-deficient modified vaccinia Ankara
“Take”	“Take” occurs	No “take” after vaccination
Inadvertent inoculation and autoinoculation	Risk exists	No risk
Serious adverse event	Risk exists	Fewer expected
Cardiac adverse events	Myo/pericarditis in 5.7 per 1,000 primary vaccinees	Risk believed to be lower than that for ACAM2000
Effectiveness	FDA assessed by comparing immunologic response and “take” rates to Dryvax*	FDA assessed by comparing immunologic response to ACAM2000 & animal studies
Administration	Percutaneously by multiple puncture technique in single dose	Subcutaneously or intradermally in 2 doses, 28 days apart

*Both ACAM2000 and Dryvax are derived from the NYC Board of Health vaccinia strain; ACAM2000 is “second generation” smallpox vaccine derived from a clone of Dryvax, purified, and produced using modern cell culture technology

Vaccination Prior to Exposure

Orthopoxvirus Vaccine Recommendations for Healthcare Providers and Laboratorians

- As of June 3rd, 2022, Advisory Committee on Immunization Practices (ACIP) recommends mpox vaccination only for:
 - Research laboratory personnel working with orthopoxviruses
 - Clinical laboratory personnel performing diagnostic testing for orthopoxviruses
 - Orthopoxvirus and health care worker response teams designated by appropriate public health and antiterror authorities
- Persons who administer ACAM2000 or care for patients with infection with replication-competent viruses should be offered the vaccine

Mpox Vaccination Indications: Sexual History Risk Factors (1/2)

- Mpox vaccination should be offered to adults and adolescents, who over the last 6 months:

were diagnosed with a sexually transmitted infection

OR

had a new sex partner

AND

are gay, bisexual, or are other men who have sex with men

OR

are transgender or nonbinary

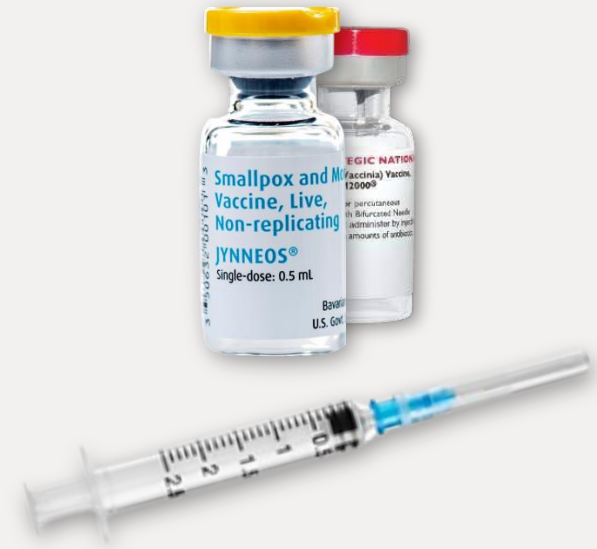Mpox Vaccination Indications: Sexual History Risk Factors (2/2)

- Mpox vaccination should be offered to:
 - Anyone who has had sex during the last 6 months:
 - At a commercial sex venue or other social gathering
 - In association with a large public event in an area with ongoing mpox transmission
 - With a partner with the above risks
 - People with HIV infection or other causes of immunosuppression who have had recent or anticipate possible future risk of mpox exposure

Postexposure Prophylaxis (PEP) and Monitoring

Vaccine Strategy Considerations

- Health departments have received allocations of JYNNEOS vaccine based on jurisdictional numbers of¹:
 - HIV+ men who have sex with men (MSM)
 - HIV PrEP*-eligible MSM
- JYNNEOS is being distributed to jurisdictions and provided to patients at no cost



*Pre-exposure prophylaxis

Mpox Vaccine Postexposure Prophylaxis¹

- Risk exposure assessment determines need for vaccination of close contacts²
- Initiate postexposure prophylaxis (PEP)*:
 - Within 4 days of suspected exposure to minimize disease incidence
 - From 4–14 days after suspected exposure to reduce illness severity

*Based on data from live, replicating vaccinia virus vaccines for smallpox

PEP and Monitoring for Healthcare Setting Exposures (1/3)

Risk level of exposure	Exposure characteristics	Recommend Monitoring	Recommend PEP ¹
Higher	<p>Unprotected contact between an exposed individual’s broken skin or mucous membranes and the skin lesions or bodily fluids from a patient with mpox (e.g., inadvertent splashes of patient saliva to the eyes or mouth of a person), or soiled materials (e.g., linens, clothing) OR</p> <p>Being inside the patient’s room or within 6 feet of a patient with mpox during any medical procedures that may create aerosols from oral secretions (e.g., cardiopulmonary resuscitation, intubation) or activities that may resuspend dried exudates (e.g., shaking of soiled linens) without wearing a NIOSH-approved particulate respirator with N95 filters or higher and eye protection</p>	Yes	Recommended

Footnotes may be found in the PowerPoint notes section

PEP and Monitoring for Healthcare Setting Exposures (2/3)

Risk level of exposure	Exposure characteristics	Recommend Monitoring	Recommend PEP ¹
Intermediate	<p>Being within 6 feet for a total of 3 hours or more (cumulative) of an unmasked patient with mpox without wearing a facemask or respirator OR</p> <p>Unprotected contact between an exposed individual's intact skin and the skin lesions or bodily fluids from a patient with mpox, or soiled materials (e.g., linens, clothing) OR</p> <p>Activities resulting in contact between an exposed individual's clothing and the patient with mpox's skin lesions or bodily fluids, or their soiled materials (e.g., during turning, bathing, or assisting with transfer) while not wearing a gown</p>	Yes	Informed clinical decision making recommended on an individual basis to determine whether benefits of PEP outweigh risks of transmission or severe disease ¹¹

Footnotes may be found in the PowerPoint notes section

PEP and Monitoring for Healthcare Setting Exposures (3/3)

Risk level of exposure	Exposure characteristics	Recommend Monitoring	Recommend PEP [¶]
Lower	Entry into the contaminated room or patient care area of a patient with mpox without wearing all recommended PPE and in the absence of any exposures above	Yes	None
No Risk	No contact with the patient with mpox, their contaminated materials, nor entry into the contaminated patient room or care area	No	None

Footnotes may be found in the PowerPoint notes section

PEP and Monitoring for Community Exposures (1/3)

Degree of exposure	Exposure characteristics	Recommend Monitoring	Recommend PEP [†]
High	<p>Contact between an exposed individual's broken skin or mucous membranes with the skin lesions or bodily fluids from a person with mpox OR</p> <p>Any sexual or intimate contact involving mucous membranes (e.g., kissing, oral-genital, oral-anal, vaginal, or anal sex (insertive or receptive)) with a person with mpox OR</p> <p>Contact between an exposed individual's broken skin or mucous membranes with materials (e.g., linens, clothing, objects, sex toys) that have contacted the skin lesions or bodily fluids of a person with mpox (e.g., sharing food, handling or sharing of linens used by a person with mpox without having been disinfected[†] or laundered)</p>	Yes	Recommended

Footnotes may be found in the PowerPoint notes section

PEP and Monitoring for Community Exposures (2/3)

Degree of exposure	Exposure characteristics	Recommend Monitoring	Recommend PEP [¶]
Intermediate	<p>Being within 6 feet for a total of 3 hours or more (cumulative) of an unmasked person with mpox without wearing a surgical mask or respirator OR</p> <p>Contact between an exposed individual's intact skin with the skin lesions or bodily fluids from a person with mpox OR</p> <p>Contact between an exposed individual's intact skin with materials (e.g., linens, clothing, sex toys) that have contacted the skin lesions or bodily fluids from a person with mpox without having been disinfected[†] or laundered OR</p> <p>Contact between an exposed individual's clothing with the person with mpox's skin lesions or bodily fluids, or their soiled linens or dressings (e.g., during turning, bathing, or assisting with transfer)</p>	Yes	Informed clinical decision making recommended on an individual basis to determine if the benefits of PEP outweigh the risks

Footnotes may be found in the PowerPoint notes section

PEP and Monitoring for Community Exposures (3/3)

Degree of exposure	Exposure characteristics	Recommend Monitoring	Recommend PEP [¶]
Lower	Entry into the living space of a person with mpox (regardless of whether the person with mpox is present), and in the absence of any exposures above	Yes	None
No Risk	No contact with the person with mpox, their potentially infectious contaminated materials, nor entry into their living space	No	None

Footnotes may be found in the PowerPoint notes section

CDC and Other Mpox Consultation Services

- CDC provides consultation on mpox vaccine indications and a variety of treatment modalities, including antivirals
- For patient care consults or to obtain intravenous tecovirimat or VIGIV, contact CDC
 - Phone: (770) 488-7100
 - Email: poxvirus@cdc.gov
- To obtain brincidofovir, contact FDA
 - Phone (business hours): 301-796-3400 or 1-855-543-378
 - Phone (after hours): 301-796-8240 or 1-866-300-4374
 - Email: DDI.EIND@fda.hhs.gov

Infection Control, Isolation, and Monitoring

At Home: Infection Control

- People with mpox who do not require hospitalization should follow [CDC's Isolation and Prevention Practices for People with Mpox¹](#)
- CDC recommends that patients isolate at home for 21 days following potential exposure OR until symptoms have fully resolved

Factors influencing at-home isolation

Presence of other people or pets

Presence of children aged under 1 year, pregnant or immunocompromised people, and individuals with eczema or atopic dermatitis

Ability of the person with mpox to follow recommended precautions

At Home: Isolation and Monitoring

During the 21-day monitoring period, if:

Rash occurs

Follow isolation and prevention practices until:

1. The rash is evaluated by a healthcare provider
2. Testing is performed, if recommended by a healthcare provider
3. Results of testing are available and negative

Other signs/symptoms occur, but no rash

Follow isolation and prevention practices for 5 days, extending beyond the original 21-day monitoring period if needed

- If no new signs or symptoms develop, stop isolation and prevention practices. Monitor for the remainder of the 21-day period
- If additional signs or symptoms develop, a new 5-day isolation period starts, even if it will end after day 21

Healthcare Settings: Patient Monitoring

- Monitor asymptomatic patients in healthcare facilities who were exposed to mpox virus [for 21 days after their last exposure](#)
 - In general, isolation is not required
- During the monitoring period, assess the patient for [signs and symptoms](#) of mpox and conduct a thorough skin exam at least once daily
- Adapt postexposure risk assessment and management from [community guidance](#) or [healthcare guidance](#) according to the nature and location of a patient's exposure

Healthcare Settings: Patient Isolation

Isolation precautions

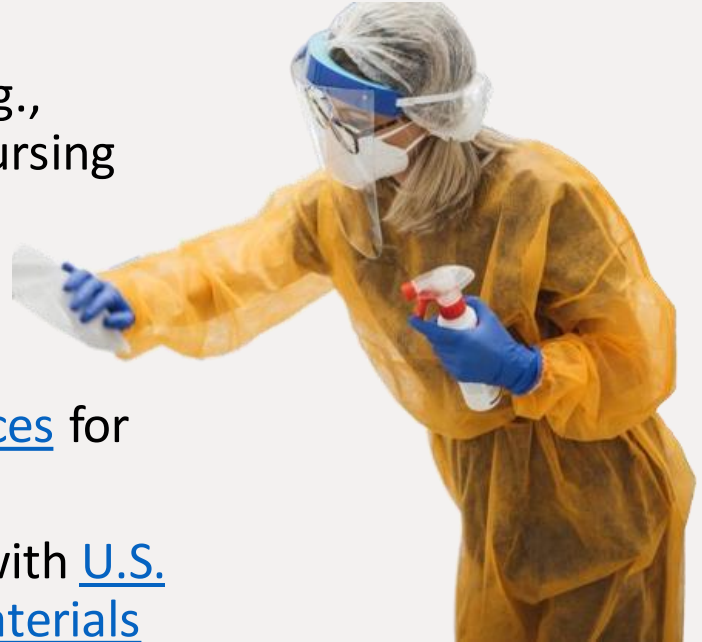- Notify infection prevention and control personnel immediately if a patient has suspected mpox infection
- Place a patient with suspected or confirmed mpox infection in a single-person room
- Special air handling is not required

Isolation duration

- Suspected mpox: **21 days** until infection is ruled out
- Confirmed mpox: **5 days after any new symptom develops**, extending beyond the original 21-day monitoring period if needed
 - Maintain until:
 - All lesions have crusted
 - Crusts have separated
 - A fresh layer of healthy skin has formed underneath
- Confer with local or state health department on decision to discontinue isolation

Healthcare Settings: Housekeeping

- For any staff cleaning mpox patient areas (e.g., housekeeping and janitorial staff, certified nursing assistant)
 - Provide appropriate personal protective equipment (PPE) and train on proper use
 - Instruct on [recommended standard practices](#) for infection control
- Perform waste management in accordance with [U.S. Department of Transportation Hazardous Materials Regulations](#)



Healthcare Settings: Healthcare Providers (HCPs)

- HCPs who enter a contaminated patient room or care area while wearing recommended PPE should be aware of the signs and symptoms of mpox
- HCPs who develop any signs or symptoms of mpox should:
 - Notify occupational health services for further evaluation
 - Leave work and begin home isolation if signs or symptoms develop while at work
 - Stay home and isolate if symptoms begin at home

Additional Information on Disinfectants for Mpox

- [EPA-Registered Disinfectants for Mpox](#)
- [Disinfecting Home and Other Non-Healthcare Settings](#)



For clinical consultation, please contact

CDC Emergency Operations Center Phone: (770) 488-7100

Email: poxvirus@cdc.gov

The findings and conclusions in this report are those of the authors and do not necessarily represent the official position of the Centers for Disease Control and Prevention.

References

Background

Slide 6: Historical Clinical Manifestations (1/2)

1. CDC [2022]. Signs and Symptoms
<https://www.cdc.gov/poxvirus/monkeypox/symptoms/index.html>
2. CDC [2022]. Clinical Recognition <https://www.cdc.gov/poxvirus/monkeypox/clinicians/clinical-recognition.html>

Slide 7: Historical Clinical Manifestations (2/2)

- CDC [2022]. Clinical Recognition <https://www.cdc.gov/poxvirus/monkeypox/clinicians/clinical-recognition.html>

Slide 9: Patients at Risk for Severe Mpox Rao AK, Schrodts CA, Minhaj FS, et al. Interim Clinical Treatment Considerations for Severe Manifestations of Mpox — United States, February 2023. MMWR Morb Mortal Wkly Rep 2023;72:232–243. DOI: <http://dx.doi.org/10.15585/mmwr.mm7209a4>

Slide 12: Mpox Complications: Other

- Rao AK, Schrodts CA, Minhaj FS, et al. Interim Clinical Treatment Considerations for Severe Manifestations of Mpox — United States, January 2023. MMWR Morb Mortal Wkly Rep. forthcoming 2023.

Epidemiology

Slide 14: Up-to-Date CDC Situation Summary

1. CDC [2023]. 2022 U.S. Map & Case Count
<https://www.cdc.gov/poxvirus/monkeypox/response/2022/us-map.html>
2. CDC [2023]. U.S. Mpox Case Trends Reported to CDC
<https://www.cdc.gov/poxvirus/monkeypox/response/2022/mpx-trends.html>
3. CDC [2023]. Mpox Outbreak Global Map
<https://www.cdc.gov/poxvirus/monkeypox/response/2022/world-map.html>
4. CDC [2023]. Mpox Cases by Age and Gender, Race/Ethnicity, and Symptoms
<https://www.cdc.gov/poxvirus/monkeypox/response/2022/demographics.html>
5. CDC [2023]. Mpox Vaccine Administration and Effectiveness
<https://www.cdc.gov/poxvirus/monkeypox/response/2022/vaccine-admin.html>
6. CDC [2022]. Lab Testing Data <https://www.cdc.gov/poxvirus/monkeypox/cases-data/lab-testing.html>
7. CDC [2022]. Mpox Technical Reports <https://www.cdc.gov/poxvirus/monkeypox/cases-data/technical-report.html>

Epidemiology

Slide 15: Transmission

1. CDC [2023]. How It Spreads. <https://www.cdc.gov/poxvirus/mpox/if-sick/transmission.html>
2. CDC [2023]. Science Brief: Detection and Transmission of Mpox (Formerly Monkeypox) Virus During the 2022 Clade IIb Outbreak. <https://www.cdc.gov/poxvirus/mpox/about/science-behind-transmission.html>
3. CDC [2023]. Isolation and Prevention Practices for People with Mpox. <https://www.cdc.gov/poxvirus/mpox/clinicians/isolation-procedures.html>
4. Miura F, Backer JA, van Rijckevorsel G, Bavalia R, Raven S, Petrignani M, Ainslie KEC, Wallinga J [2022]. Time scales of human mpox transmission in the Netherlands. Medrxiv preprint. doi: <https://doi.org/10.1101/2022.12.03.22283056>

Slide 16: High Risk Exposure Examples for Health Care Providers (HCPs)

- CDC [2022]. Infection Prevention and Control of Mpox in Healthcare Settings <https://www.cdc.gov/poxvirus/monkeypox/clinicians/infection-control-healthcare.html>

Slide 17: Intermediate Risk Exposure Examples for HCPs

- CDC [2022]. Infection Prevention and Control of Mpox in Healthcare Settings <https://www.cdc.gov/poxvirus/monkeypox/clinicians/infection-control-healthcare.html>

2022 Mpox Outbreak

Slide 19: 2022 Mpox Outbreak Signs and Symptoms

- CDC [2022]. Clinical Recognition
<https://www.cdc.gov/poxvirus/monkeypox/clinicians/clinical-recognition.html>

Slide 20: Rash Presentations (1/2)

1. Basgoz N, Brown CM, Smole SC, Madoff LC, Biddinger PD, Baugh JJ, Shenoy ES [2022]. Case 24-2022: A 31-Year-Old Man with Perianal and Penile Ulcers, Rectal Pain, and Rash. N Engl J Med. 387(6):547-556. doi: <http://dx.doi.org/10.1056/NEJMcpc2201244>
2. Miller MJ, Cash-Goldwasser S, Marx GE, et al. Severe Monkeypox in Hospitalized Patients — United States, August 10–October 10, 2022. MMWR Morb Mortal Wkly Rep 2022;71:1412–1417. doi: <http://dx.doi.org/10.15585/mmwr.mm7144e1>

Slide 25: Current U.S. Outbreak Response

1. CDC [2022]. Monitoring and Risk Assessment for Persons Exposed in the Community
<https://www.cdc.gov/poxvirus/monkeypox/clinicians/monitoring.html#exposure>

Evaluation and Diagnosis for Current Outbreak

Slide 29: Social History

- CDC [2022]. Case Definitions for Use in the 2022 Mpox Response <https://www.cdc.gov/poxvirus/monkeypox/clinicians/case-definition.html>

Slide 31: Case Definition

- CDC [2022]. Case Definitions for Use in the 2022 Mpox Response <https://www.cdc.gov/poxvirus/monkeypox/clinicians/case-definition.html>

Slide 33: CDC-Issued Specimen Collection Guidelines

1. CDC [2022]. Infection Prevention and Control of Mpox in Healthcare Settings <https://www.cdc.gov/poxvirus/monkeypox/clinicians/infection-control-healthcare.html>
2. CDC [2022]. Tips for Adequate Collection of a Lesion Specimen from a Suspect Monkeypox Virus Case https://www.cdc.gov/poxvirus/monkeypox/pdf/MPox-AdequateSpecimenCollection_508.pdf
3. CDC [2022]. Guidelines for Collecting and Handling Specimens for Mpox Testing <https://www.cdc.gov/poxvirus/monkeypox/clinicians/prep-collection-specimens.html>

Evaluation and Diagnosis for Current Outbreak

Slide 33: CDC-Issued Specimen Collection Guidelines (cont)

4. CDC [2022]. Additional Testing of Biopsy Tissues in Severe Mpox Infections <https://www.cdc.gov/poxvirus/monkeypox/clinicians/prep-collection-specimens/biopsies.html>

Slide 34: Testing for Mpox

1. CDC [2022]. Testing Patients for Monkeypox <https://www.cdc.gov/poxvirus/monkeypox/pdf/MPoxTestingPatients.pdf>
2. CDC [2019]. The Laboratory Response Network Partners in Preparedness <https://emergency.cdc.gov/lrn/index.asp>
3. CSTE After Hours Epi On-call: <https://www.cste.org/page/EpiOnCall>
4. CDC [2022]. Submitting Specimens to CDC <https://www.cdc.gov/laboratory/specimen-submission/>

Evaluation and Diagnosis for Current Outbreak

Slide 35: Additional Diagnostic Considerations

1. Rao AK, Schrodtt CA, Minhaj FS, et al. Interim Clinical Treatment Considerations for Severe Manifestations of Mpox — United States, January 2023. MMWR Morb Mortal Wkly Rep 2023; Forthcoming in 2023.
2. CDC [2021]. Sexually Transmitted Infections (STI) Treatment Guidelines, 2021. [STI Treatment Guidelines \(cdc.gov\)](#)

Differential Diagnosis

Slide 38 Genital Ulcer Disease Diagnostic Evaluation

- CDC [2021]. Diseases Characterized by Genital, Anal, or Perianal Ulcers. <https://www.cdc.gov/std/treatment-guidelines/genital-ulcers.htm>

Slide 48: Genital (Oral) Ulcer Disease: Mpox

1. Patrocinio-Jesus R, Peruzzu F [2022]. Monkeypox Genital Lesions. N Engl J Med. 387(1):66. doi: 10.1056/NEJMicm2206893.

Mpox and Mpox Look Alikes

Slide 49: Genital (Oral) Ulcer Disease: Primary Syphilis

1. Patrocinio-Jesus R, Peruzzu F [2022]. Monkeypox Genital Lesions. N Engl J Med. 387(1):66. doi: 10.1056/NEJMicm2206893.

Slide 50 & 51: Oral Mucosal Lesions: Mpox and Aphthous Ulcer

1. https://www.cdc.gov/nchs/ppt/icd9/att_mucositis_sep05.ppt

Slide 52-54: Crusted Skin Lesions/Scabs: Mpox , Genital Herpes, and Herpes Zoster

1. Patrocinio-Jesus R, Peruzzu F [2022]. Monkeypox Genital Lesions. N Engl J Med. 387(1):66. doi: 10.1056/NEJMicm2206893.

Treatment

Slide 56: Mpox Prognostic Indicators (1/2)

1. CDC [2022]. Treatment Information for Healthcare Professionals
<https://www.cdc.gov/poxvirus/monkeypox/clinicians/treatment.html>
2. CDC [2022]. Clinical Considerations for Pain Management of Mpox
<https://www.cdc.gov/poxvirus/monkeypox/clinicians/pain-management.html>
3. American Academy of Dermatology and the American Academy of Dermatology Associates [2022]. Monkeypox Caring for the Skin.
https://assets.ctfassets.net/1ny4yoivrqia/205qKUkE21zKDDSL3KBDq/46124bcc4bf0c0fabb_e7a84a490efe73/AAD-Monkeypox-Caring-for-Skin.pdf
4. Miller MJ, Cash-Goldwasser S, Marx GE, et al. Severe Monkeypox in Hospitalized Patients — United States, August 10–October 10, 2022. MMWR Morb Mortal Wkly Rep 2022;71:1412–1417. DOI: <http://dx.doi.org/10.15585/mmwr.mm7144e1>

Treatment

Slide 57: Mpox Prognostic Indicators (2/2)

- CDC [2022]. Severe Monkeypox in Hospitalized Patients — United States, August 10–October 10, 2022 <https://www.cdc.gov/mmwr/volumes/71/wr/mm7144e1.htm#contribAff>

Treatment

Slide 58: Mpox Treatment Algorithm

- Rao AK, Schrodtt CA, Minhaj FS, et al. Interim Clinical Treatment Considerations for Severe Manifestations of Mpox — United States, January 2023. MMWR Morb Mortal Wkly Rep. forthcoming 2023.

Slide 59: Optimize Immune Function

- CDC [2022]. Update on Managing Monkeypox in Patients Receiving Therapeutics <https://emergency.cdc.gov/han/2022/han00481.asp>

Slide 60: Tecovirimat

- CDC [2022]. Guidance for Tecovirimat Use <https://www.cdc.gov/poxvirus/monkeypox/clinicians/Tecovirimat.html>

Slide 61: Tecovirimat Should be Considered for Patients With

- CDC [2022]. Guidance for Tecovirimat Use <https://www.cdc.gov/poxvirus/monkeypox/clinicians/Tecovirimat.html>

Treatment

Slide 62: Tecovirimat: Availability

1. U.S. Department of Health and Human Services and National Institutes for Health [2022]. Study of Tecovirimat for Human Mpox Virus <https://www.stomptpoxx.org/main>
2. CDC [2022]. Guidance for Tecovirimat Use <https://www.cdc.gov/poxvirus/monkeypox/clinicians/Tecovirimat.html>

Slide 63: Tecovirimat: Safety and Side Effects

1. Rao AK, Schrodts CA, Minhaj FS, et al. Interim Clinical Treatment Considerations for Severe Manifestations of Mpox — United States, February 2023. MMWR Morb Mortal Wkly Rep 2023;72:232–243. DOI: <http://dx.doi.org/10.15585/mmwr.mm7209a4>

Slide 64: Cidofovir and Brincidofovir

- CDC [2022]. Treatment Information for Healthcare Professionals. <https://www.cdc.gov/poxvirus/monkeypox/clinicians/treatment.html>

Treatment

Slide 65: Ocular Mpox Treatment

- CDC [2022]. Interim Clinical Considerations for Management of Ocular Mpox Virus Infection
<https://www.cdc.gov/poxvirus/monkeypox/clinicians/ocular-infection.html>

Slide 66: Vaccinia Immune Globulin Intravenous (VIGIV)

- U.S. Food and Drug Administration (FDA) [2018]. Vaccinia Immune Globulin Intravenous (Human)
<https://www.fda.gov/vaccines-blood-biologics/approved-blood-products/vaccinia-immune-globulin-intravenous-human>
- CDC [2022q]. Treatment Information for Healthcare Professionals
https://www.cdc.gov/poxvirus/monkeypox/clinicians/treatment.html#anchor_1655488353796

Mpox Vaccination

Slide 68: JYNNEOS Vaccine

1. U.S. Food and Drug Administration (FDA) [2022]. Jynneos <https://www.fda.gov/vaccines-blood-biologics/jynneos>
2. CDC [2022]. JYNNEOS Smallpox and Monkeypox Vaccine: ALTERNATIVE REGIMEN Standing Orders for Administering Vaccine Intradermally <https://www.cdc.gov/poxvirus/monkeypox/files/interim-considerations/monkeypox-jynneos-standing-orders-alt-dose.pdf>
3. CDC [2022]. JYNNEOS Smallpox and Monkeypox Vaccine: STANDARD REGIMEN Standing Orders for Administering Vaccine Subcutaneously <https://www.cdc.gov/poxvirus/monkeypox/files/interim-considerations/monkeypox-jynneos-standing-orders-stand.pdf>

Slide 69: JYNNEOS Vaccine: Efficacy

1. Payne AB, Ray LC, Cole MM, et al. Reduced Risk for Mpox After Receipt of 1 or 2 Doses of JYNNEOS Vaccine Compared with Risk Among Unvaccinated Persons — 43 U.S. Jurisdictions, July 31–October 1, 2022. MMWR Morb Mortal Wkly Rep 2022;71:1560–1564. DOI: <http://dx.doi.org/10.15585/mmwr.mm7149a5>

Mpox Vaccination

Slide 70: JYNNEOS Vaccine: Safety and Side Effects

- CDC [2022]. ACAM2000 Vaccine <https://www.cdc.gov/poxvirus/monkeypox/interim-considerations/acam2000-vaccine.html>

Slide 71: ACAM2000 Vaccine

- CDC [2022]. ACAM2000 Vaccine <https://www.cdc.gov/poxvirus/monkeypox/interim-considerations/acam2000-vaccine.html>

Slide 72: ACAM2000 Vaccine: Efficacy

1. Fine PE, Jezek Z, Grab B, Dixon H [1988]. The transmission potential of monkeypox virus in human populations. Int J Epidemiol. 17(3):643-50. <https://doi.org/10.1093/ije/17.3.643>.
2. U.S. Food and Drug Administration [2022]. ACAM2000 (Smallpox Vaccine) Questions and Answers. <https://www.fda.gov/vaccines-blood-biologics/vaccines/acam2000-smallpox-vaccine-questions-and-answers>
3. CDC [2022u]. ACAM2000 Vaccine <https://www.cdc.gov/poxvirus/monkeypox/interim-considerations/acam2000-vaccine.html>

Mpox Vaccination

Slide 73: ACAM2000 Vaccine: Safety and Side Effects

1. U.S. Food and Drug Administration [2022]. ACAM2000 (Smallpox Vaccine) Questions and Answers. <https://www.fda.gov/vaccines-blood-biologics/vaccines/acam2000-smallpox-vaccine-questions-and-answers>
2. CDC [2022u]. ACAM2000 Vaccine <https://www.cdc.gov/poxvirus/monkeypox/interim-considerations/acam2000-vaccine.html>

Slide 74: Eczema Vaccinatum from ACAM2000 Vaccine Efficacy

1. Centers for Disease Control and Prevention (CDC) [2007]. Household transmission of vaccinia virus from contact with a military smallpox vaccinee--Illinois and Indiana, 2007. MMWR Morb Mortal Wkly Rep. 56(19):478-81. PMID: 17510612. <https://pubmed.ncbi.nlm.nih.gov/17510612/>

Slide 76: Contraindications: ACAM2000 and JYNNEOS

- CDC [2002]. Infection Prevention and Control of Mpox in Healthcare Settings <https://www.cdc.gov/poxvirus/monkeypox/clinicians/infection-control-healthcare.html>

Pre-Exposure Prophylaxis

Slide 79: Orthopoxvirus Vaccine Recommendations for Healthcare Providers and Laboratorians

- Rao AK, Petersen BW, Whitehill F, et al. Use of JYNNEOS (Smallpox and Monkeypox Vaccine, Live, Nonreplicating) for Preexposure Vaccination of Persons at Risk for Occupational Exposure to Orthopoxviruses: Recommendations of the Advisory Committee on Immunization Practices — United States, 2022. MMWR Morb Mortal Wkly Rep 2022;71:734–742. DOI: <http://dx.doi.org/10.15585/mmwr.mm7122e1>

Slide 80-81: Mpox Vaccination Indications: Sexual History Risk Factors

- CDC [2023]. Mpox Vaccination Basics <https://www.cdc.gov/poxvirus/monkeypox/vaccines/index.html>

Postexposure Prophylaxis (PEP) and Monitoring

Slide 83: Vaccine Strategy Considerations

1. ASPR [2022]. JYNNEOS Vaccine Distribution by Jurisdiction.
<https://aspr.hhs.gov/SNS/Pages/JYNNEOS-Distribution.aspx>

Slide 84: Mpox Vaccine Post-Exposure Prophylaxis

1. CDC [2022]. Interim Clinical Considerations for Use of JYNNEOS and ACAM2000 Vaccines during the 2022 U.S. Mpox Outbreak. [Interim Clinical Considerations for Use of JYNNEOS and ACAM2000 Vaccines during the 2022 U.S. Mpox Outbreak | Mpox | Poxvirus | CDC](#)
2. CDC [2022]. Monitoring and Risk Assessment for Persons Exposed in the Community.
<https://www.cdc.gov/poxvirus/monkeypox/clinicians/monitoring.html#exposure>

Slides 85-87: PEP and Monitoring for Healthcare Setting Exposures

- CDC [2022]. Infection Prevention and Control of Mpox in Healthcare Settings

<https://www.cdc.gov/poxvirus/monkeypox/clinicians/infection-control-healthcare.html>

Infection Control, Isolation, and Monitoring

Slides 88-90: PEP and Monitoring for Community Exposures

- CDC [2022]. Monitoring and Risk Assessment for Persons Exposed in the Community
<https://www.cdc.gov/poxvirus/monkeypox/clinicians/monitoring.html#exposure>

Slide 93: At Home: Infection Control

1. CDC [2022]. Isolation and Infection Control At Home
<https://www.cdc.gov/poxvirus/monkeypox/clinicians/infection-control-home.html>

Slide 94: At Home: Isolation and Monitoring

- CDC [2022]. Monitoring and Risk Assessment for Persons Exposed in the Community
<https://www.cdc.gov/poxvirus/monkeypox/clinicians/monitoring.html#exposure>

Slide 95: Healthcare Settings: Patient Monitoring

- CDC [2022]. Infection Prevention and Control of Mpox in Healthcare Settings
<https://www.cdc.gov/poxvirus/monkeypox/clinicians/infection-control-healthcare.html>

Infection Control, Isolation, and Monitoring

Slide 96: Healthcare Settings: Patient Isolation

- CDC [2022]. Infection Prevention and Control of Mpox in Healthcare Settings
<https://www.cdc.gov/poxvirus/monkeypox/clinicians/infection-control-healthcare.html>

Slide 97: Healthcare Settings: Housekeeping

- CDC [2022]. Infection Prevention and Control of Mpox in Healthcare Settings
<https://www.cdc.gov/poxvirus/monkeypox/clinicians/infection-control-healthcare.html>

Slide 98: Healthcare Settings: Healthcare Providers (HCPs)

- CDC [2022]. Infection Prevention and Control of Mpox in Healthcare Settings
<https://www.cdc.gov/poxvirus/monkeypox/clinicians/infection-control-healthcare.html>